Clinical Anatomy 17:503–512 (2004)

ORIGINAL COMMUNICATION

Anatomic Survey of the Common Fibular Nerve and Its Branching Pattern With Regard to the Intermuscular Septa of the Leg

F. AIGNER,[1,2*] S. LONGATO,[1] A. GARDETTO,[3] M. DEIBL,[4] H. FRITSCH,[1] AND H. PIZA-KATZER[3]

[1]*Institute of Anatomy, Histology and Embryology, Department of Functional and Clinical Anatomy, Medical University of Innsbruck, Innsbruck, Austria*
[2]*Department of General and Transplant Surgery, Medical University of Innsbruck, Austria*
[3]*Department of Plastic and Reconstructive Surgery, Medical University of Innsbruck, Innsbruck, Austria and Ludwig-Boltzmann-Institute for Quality Control in Plastic Surgery, Austria*
[4]*Institute of Biostatistics, Medical University of Innsbruck, Innsbruck, Austria*

Compression syndromes of the common fibular nerve and its branches frequently occur primarily as well as secondarily to trauma and surgery. A keen knowledge of the course and the relationship of the deep fibular nerve to adjacent anatomical structures in the proximal leg is mandatory. Previous literature often lacks detailed information on the course of the deep fibular nerve and is based on a limited number of observations. The aim of this study was to investigate the common fibular nerve and its branching pattern with special regard to the relationship between the deep fibular nerve and the anterior intermuscular septum of the leg. Variations in the course of the fibular nerve were demonstrated. The fibular compartments of the leg ($n = 111$) were dissected in 57 embalmed cadavers and included: 1) investigation of the number of muscular branches; 2) entering passages to the respective compartments of the leg; and 3) the relationship between the fibularis longus muscle and the deep fibular nerve. The most proximal muscular branch of the deep fibular nerve directly "pierced" the anterior intermuscular septum of the leg. Narrow passages within the fibular compartment and, in consequence, areas of possible higher incidence of nerve compression were suggested at the level of the intermuscular septa of the leg, between the two distinct portions of the fibularis longus muscle and the crossing of the supplying vessels. There were hardly ever statistically significant differences between the two sides or male and female gender. According to our results, the anterior intermuscular septum of the leg may be regarded as an important landmark for the surgeon when dissecting the muscular branches of the deep fibular nerve. The variable branching pattern of the deep fibular nerve within the fibular compartment of the leg should be taken into account. Clin. Anat. 17:503–512, 2004.

Key words: deep fibular nerve; fibular compartment of the leg; compression

INTRODUCTION

The anatomy and topography of the common fibular nerve (CFN) has been described in many anatomical textbooks (Parsons Schaeffer, 1942; Corning, 1949; Töndury, 1949; Anson, 1950; Hafferl, 1953; Hamilton, 1956; Hollinshead, 1958; Sieglbauer, 1963; Lang and Wachsmuth, 1972; Leonhardt et al., 1988; Thiel, 1996; Williams et al., 1989; Healey and Hodge, 1990). The CFN courses around the fibular head, first lying behind the tendon of the biceps femoris and then entering the fibular or lateral compartment of the leg by passing the posterior intermuscular septum of the leg (PIS) in an oblique, downward direction. The CFN divides into a) the superficial fibular nerve with motor branches to the fibularis longus and the fibularis brevis muscles, and b) the deep fibular nerve (DFN), which innervates the tibialis anterior, extensor digito-

*Correspondence to: Dr. Felix Aigner, Department of General and Transplant Surgery, Medical University Innsbruck, Anichstrasse 35, A-6010 Innsbruck, Austria. E-mail: felix.aigner@uibk.ac.at

Received 28 May 2003; Revised 12 August 2003

Published online in Wiley InterScience (www.interscience.wiley.com). DOI 10.1002/ca.20007

rum longus, and extensor hallucis longus muscles in the extensor or anterior compartment of the leg.

The description of the course, however, and the branching pattern of the DFN within the compartments of the leg is rather superficial. It lacks detailed information about the relationship between the DFN and the anterior intermuscular septum of the leg (AIS). Clinical papers concerning the DFN are based on a very limited number of specimens (Lawrence and Botte, 1995; Aydogdu et al., 1996; Takeda et al., 2001). It is of clinical importance for surgeons to be aware of the regional topography of the DFN within the proximal fibular compartment, especially regarding the distribution of its muscular branches, for instance while performing correction osteotomies of the leg, osteosynthesis after knee fracture, or luxation and microsurgical fibular nerve reconstruction. High-resolution sonography of the peripheral nervous system (Peer and Bodner, 2003) demands macroscopic observations of the branching pattern of the DFN as a valuable addition to the description of this topographically complex region.

The aim of this study was to investigate the anatomy and variability of the branching pattern of the CFN and its divisions in the proximal portion of the leg. Moreover, a detailed description of the relationship of the DFN to the adjacent fibularis longus muscle, the AIS, and the proximal vascular pedicle supplying the fibularis longus muscle was given for better understanding of the compression syndromes of the fibular nerves with regard to the complex topography of the proximal portion of the leg.

Finally, areas of possible higher incidence for nerve compression, idiopathic or secondarily to trauma or surgery, were described in this anatomical investigation. Possible differences in gender and variations in the course of the fibular nerves were taken into consideration and compared with the findings in former literature (Reimann, 1983; Adkison et al., 1991; Kudoh et al., 1999).

MATERIALS AND METHODS

We carried out dissection of the proximal fibular and extensor compartments in 111 legs of 57 Caucasian adult cadavers (34 female and 23 male, age range = 55–100 years, mean age = 81.6) obtained from the dissecting course at our Institute. The cadavers were preserved by a method described by Platzer et al. (1978). Three legs were excluded from our study because of "below-knee" amputation in two cases (one right and one left leg) and unintended destruction of the investigated site in one left leg. Dissections were carried out by two specially trained faculties.

After skin removal, the deep fascia of the leg was longitudinally incised and the trunk of the CFN was identified running around the fibular head. The part of the fascia covering the lateral compartment and the fibularis longus muscle, which was cut about 2 cm distally to its origin on the fibular head, were reflected posteriorly, and an adipose tissue sheath was removed to show the branching pattern of the DFN. The intermuscular septa of the leg were maintained to demonstrate the entering points of the fibular nerves to the respective compartment. The branching pattern of the CFN and DFN, their calibers, their relationships to the fibularis longus muscle and the intermuscular septa and variations in the course of the nerves were documented and transferred to a scheme on the scale of 1:1 (Fig. 1).

A clearly palpable bony crest at the inferior margin of the fibular head, which referred to the proximal epiphysial line (Fig. 2) was used as a constant reference point (Gardner et al., 1969). This landmark could be also detected by means of conventional radiography (Meschan, 1975) as well as during physical examination and surgical dissection. For interpersonal assessment the apex of the fibular head was not considered because of the extreme statistical scattering and the significant difference in height to the other side (Brenner and Krimbacher, 1995). Moreover, the apex was usually covered by the fibular collateral ligament and the inserting biceps femoris muscle, which made direct measurement more difficult without dissecting the whole fibular head. The distance between the cranial margin of the lateral tibial condyle and the tip of the lateral malleolus was defined as the leg length.

The parameters were measured by means of a sliding caliper (Fig. 3) and registered in millimeters (mm).

Statistical Analysis

Values in the text were expressed as range and means ± SD. Differences in gender and between left and right leg were tested by the two-tailed unpaired and paired Student's *t*-test for continuous, normally distributed data, depending on the type of the variables. Univariate correlations were carried out with use of Kendall's Tau or Pearson's Correlation coefficient, depending on the type of the variables. Statistical significance was defined as $P < 0.05$. SPSS for Windows 11.0 software (Chicago, IL) was used for all analyses.

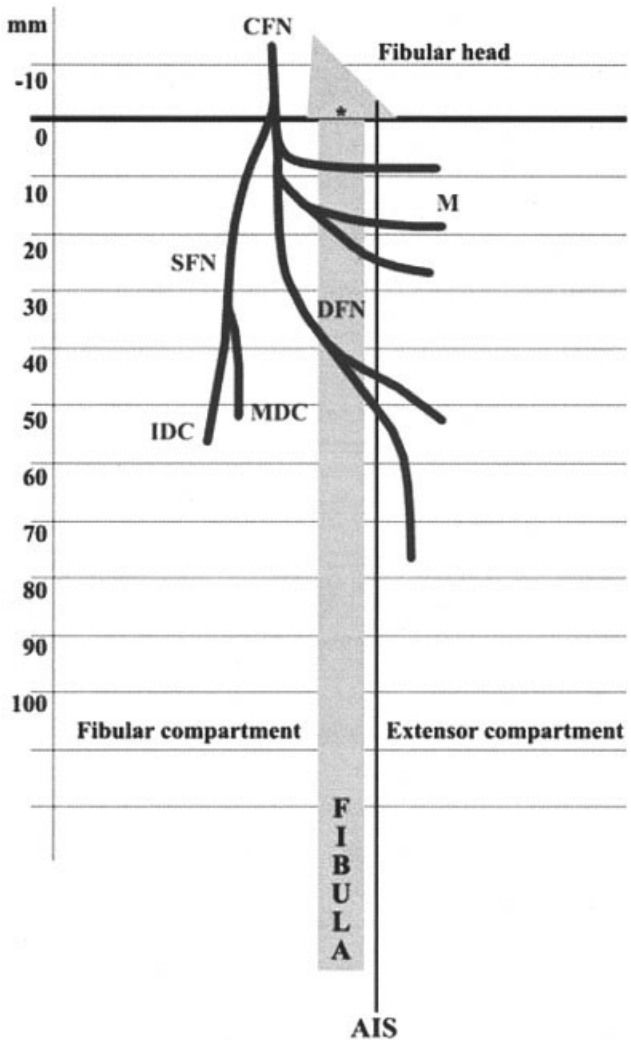

Fig. 1. Schematic illustration of the investigated site of a right leg, also used as a scale during dissections. The typical division of the common fibular nerve (CFN), the course of the deep fibular nerve (DFN) and its muscular branches (M) passing the anterior intermuscular septum of the leg (AIS) are demonstrated. SFN, superficial fibular nerve, intermediate (IDC) and medial (MDC) dorsal cutaneous nerve. *Reference point.

RESULTS

The leg length was 378 mm ± 24 mm (mean) and significantly different in gender ($P = 0.001$), but not between left and right leg ($P = 0.150$). It was the only value that showed significant difference in gender comparison.

The division of the CFN into the superficial and the deep fibular nerve was found outside the fibular compartment of the leg, which was bordered by the thin PIS dorsally and the coarse AIS ventrally, in 90 of the dissected specimens (81.1%) at a mean level 9.6 mm proximal to the reference point. There was no statistically significant side difference ($P = 0.466$) between right and left leg. In 21 legs (18.9%) the division of the CFN was situated under the tendinous arch formed by the PIS and the origin of the fibularis longus and soleus muscles at the entrance to the fibular compartment (Table 1). The CFN and its main branches ran through this tendinous arch in 104 of the dissected specimens (93.7%), whereas a smaller amount of nerves directly perforated the PIS (6.3%).

An average of three muscular branches (Table 2) arose from the trunk of the DFN *within* the fibular compartment and passed the AIS innervating the extensor digitorum longus and tibialis anterior muscles (Fig. 4). The most proximal ramification reached the tibialis anterior muscle by running deep to extensor digitorum longus. The proximal portion of the latter, which was attached to the fibrous AIS laterally to tibialis anterior, was innervated by the distal two or three muscular branches of the DFN.

The distances of these branches passing the AIS from the reference point are demonstrated in Table 3. The most proximal muscular branch of the DFN always directly "pierced" the AIS at a level, where the AIS was anchored to the neck of the fibula and formed an osteofibrous hiatus completed by the shaft of the fibula more distally (Fig. 5). The other muscular branches, the trunk of the DFN and the vascular pedicle supplying the proximal portion of the fibularis longus muscle, passed the AIS underneath its inferior margin. The vascular pedicle (Fig. 6) could be traced back to the anterior tibial vessels and crossed superficially to the DFN in 91 legs (82%) and deep to the DFN in 17 legs (15.3%).

Detailed information on further divisions of the trunk of the DFN *within* the fibular compartment and the level of passing the AIS are shown in Tables 2–3 and Figure 7, whereas an additional division of the DFN exactly within the osteofibrous hiatus between fibular and extensor compartment of the leg was found in 36 legs (32.4%). The relationships between the DFN and the fibularis longus muscle within the fibular compartment of the leg and the AIS at the entrance to the extensor compartment of the leg are demonstrated in Table 4 and Figure 4. The way the DFN passed the AIS was the only parameter that did not show a significant correlation between the right and the left leg ($P = 0.076$, Table 4).

Finally, the angle between the trunk of the DFN and the AIS (mean = 27° ± 5.7°) and the calibers of the CFN outside the fibular compartment and the DFN within the compartment after giving off the muscular branches were measured (CFN = 5.5 ± 0.95 mm, ranging from 4–10 mm; DFN = 2.8 ± 0.66 mm, ranging from 2–4 mm).

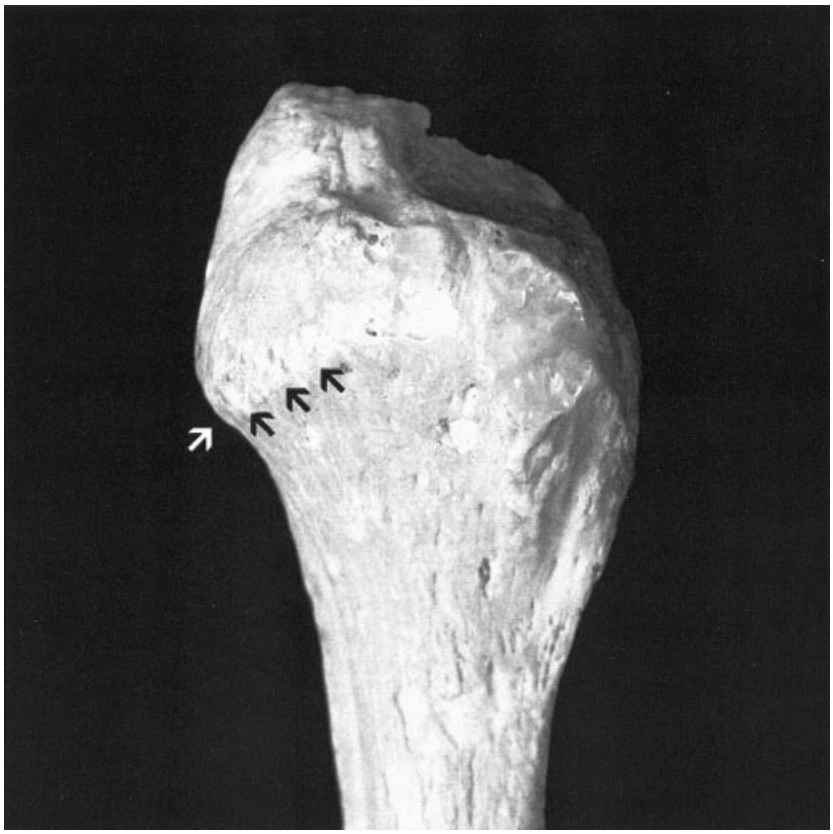

Fig. 2. Antero-lateral aspect of a right fibula. The fibular head is shown with the bony crest that refers to the former epiphysial line (arrows) and is clearly palpable and used as the reference point for the measurements.

Variations

In 19 legs (17.1%) variations in the course of the superficial and the deep fibular nerves could be detected:

- One accessory DFN (0.9%) was found following the course of the superficial fibular nerve within the fibular compartment of the leg. It curled around the lateral malleolus and innervated the

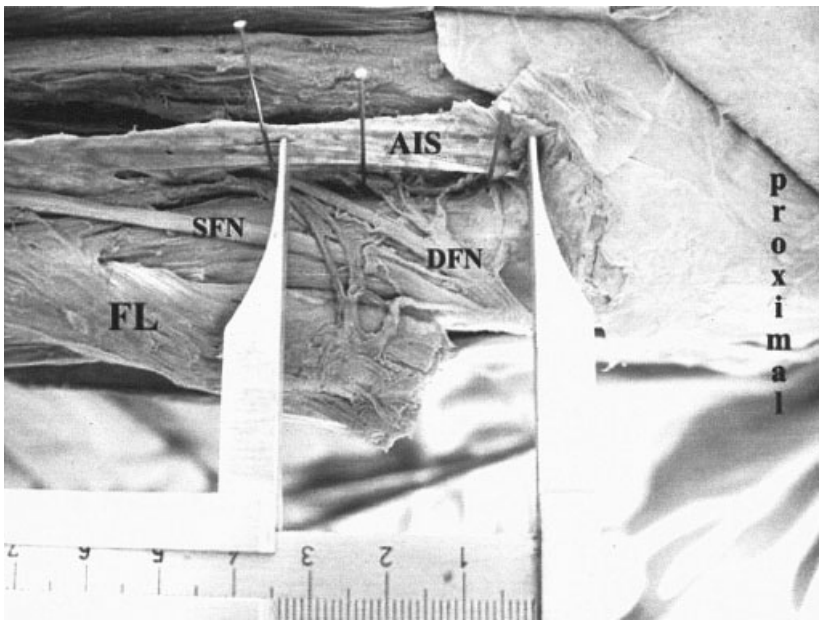

Fig. 3. Lateral aspect of a left leg showing the branching pattern of the common fibular nerve within the proximal fibular compartment. The fibularis longus muscle (FL) is cut and reflected posteriorly. Needles indicate the passage of the deep fibular nerve (DFN) and its muscular branches through the anterior intermuscular septum of the leg (AIS). The measurements were carried out with a sliding caliper. SFN, superficial fibular nerve.

TABLE 1. Level of Division of the CFN[a]

Relationship between the division of the CFN and the fibular compartment of the leg	*n* (%)	Mean distance from reference point ± SD
Outside the fibular compartment	90 (81.1%)	9.6 ± 5.6 mm proximal
At the level of the PIS	21 (18.9%)	1.5 ± 3.3 mm distal
Total	111 (100%)	

[a]CFN, common fibular nerve; PIS, posterior intermuscular septum of the leg; SD, standard deviation.

extensor digitorum brevis (Ruge, 1878a; Bryce, 1897; Kudoh et al., 1999).

- In one case (0.9%) the DFN released an additional motor branch to the fibularis longus apart from its motor branches to the extensor muscles.
- Two legs (1.8%) showed a DFN with regular course through the AIS (Fig. 8a), but giving off the medial and the intermediate dorsal cutaneous nerves within the extensor compartment. Both are usually arising from the superficial fibular nerve innervating the dorsum of the foot (Hafferl, 1953; Hollinshead, 1958; Gardner et al., 1969). The superficial fibular nerve only consisted of muscular branches to the fibularis muscles.
- An accessory sensory nerve (Fig. 8b) was found in six legs (5.4%), that seemed to originate from the DFN, but shared an independent origin from the CFN passing the AIS on an average of 70.7 mm distally to the reference point (range = 55–108 mm). This accessory fibular nerve formed the medial dorsal cutaneous nerve within the extensor compartment and has also been described as the accessory superficial fibular nerve by some authors (Ruge, 1878a; Reimann, 1984). The intermediate dorsal cutaneous nerve showed a regular course through the fibular compartment arising from the superficial fibular nerve.
- Five legs (4.5%) showed a superficial fibular nerve dividing into medial and intermediate dorsal cutaneous nerve within the fibular compartment before piercing the deep fascia of the leg. In one of the legs, the medial dorsal cutaneous nerve passed the AIS entering the extensor compartment.
- In four cases (3.6 %) the superficial fibular nerve left the fibular compartment by passing the AIS 76–105 mm distally to the reference point (mean = 86.5 mm) and formed the medial and intermediate dorsal cutaneous nerves within the extensor compartment (Fig. 8c).

DISCUSSION

The CFN and its superficial course in the lateral section of the proximal leg is a "hot spot" in traumatology and reconstructive surgery. A tight short leg plaster cast, ganglia of the tibiofibular joint and overt stretching induced by knee fracture or luxation may cause complete or partial CFN damage, especially in proximity to the fibular head. Also iatrogenic nerve damage during osteosynthesis of the proximal tibia or correction osteotomies at the leg are followed by consecutive loss of sensory and "foot drop" syndromes.

The DFN and its branching pattern showed a close proximity to the adjacent bones, muscles or fascial structures in the proximal fibular compartment of the leg. Sections of the DFN, where higher risk of nerve compression in case of increasing intramuscular pressure was supposed, should be seriously taken into surgical consideration. They have been rarely described in anatomical and clinical literature (Leonhardt et al., 1988; Dellon et al., 2002).

Our anatomical study on 111 legs concentrated on the branching pattern of the CFN with regard to its relationship to the above mentioned anatomical structures and variations in the proximal course of the nerves.

According to our macroscopic data, we could predict the following regions with possible higher incidence of nerve compression during increasing intramuscular pressure within the compartments of the leg:

TABLE 2. Number of Muscular Branches and Further Divisions of the DFN Within the Fibular Compartment of the Leg[a]

Number of muscular branches	*n* (%)	Number of further divisions of the DFN	*n* (%)
0	—	0[b]	62 (55.9%)
1	9 (8.1%)	1	30 (27.0%)
2	31 (27.9%)	2	14 (12.6%)
3	39 (35.1%)	3	4 (3.6%)
4	26 (23.5%)	4	1 (0.9%)
5	5 (4.5%)	5	—
6	1 (0.9%)	6	—
Total	111 (100%)	Total	111 (100%)
Correlation between right and left leg	$P = 0.032$*		$P = 0.003$**

[a]DFN, deep fibular nerve.
[b]Trunk of the DFN remains single within the fibular compartment.
[c]Correlation is significant at the 0.05 level.
[d]Correlation is significant at the 0.01 level.

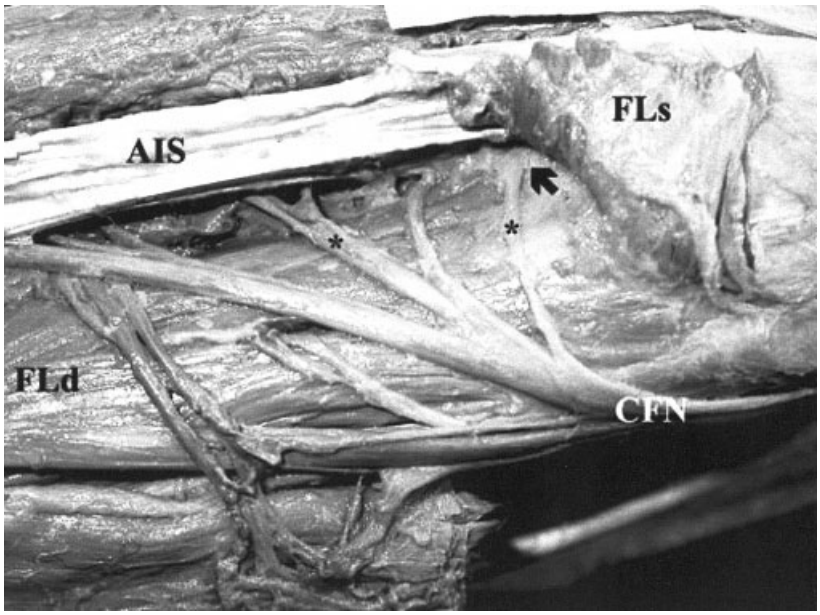

Fig. 4. Lateral aspect of a proximal left leg showing the muscular branches of the deep fibular nerve (*) and their passage through the anterior intermuscular septum of the leg (AIS). The most proximal muscular branch directly pierces the AIS (arrow). CFN, common fibular nerve; FLs, superficial head of the fibularis longus muscle reflected upwards; FLd, deep head of the fibularis longus muscle.

1. The entering point of the main branches of the CFN to the fibular compartment of the leg through the described tendinous arch formed by the PIS and the fibularis longus muscle.
2. The division of the DFN between the "two heads" of the fibularis longus muscle in 30 legs (27%).
3. The piercing point of the proximal muscular branch of the DFN through the AIS and the passage of the DFN and the distal muscular branches toward the extensor compartment.
4. The area, where the DFN and its branches are crossed by the proximal vascular pedicle to the fibularis muscles (ventrally, 82%; dorsally, 15%).

TABLE 3. Distances of the DFN and the Vascular Pedicle of the Fibularis Longus Muscle From the Reference Point at the Level of the AIS

	Mean distance from reference point ± SD	Range (min/max)	Side difference
Most proximal muscular branch	8.3 ± 4.4 mm	(−5 mm/20 mm)	$P = 0.261$
Most distal muscular branch	24.2 ± 9.5 mm	(7 mm/60 mm)	$P = 0.991$
Trunk of the DFN	44.6 ± 9.8 mm	(24 mm/76 mm)	$P = 0.785$
Proximal vascular pedicle	26.2 ± 8.1 mm	(9 mm/48 mm)	$P = 0.779$

AIS, anterior intermuscular septum of the leg; DFN, deep fibular nerve.

In the majority of the investigated legs (93.7%) the main branches of the CFN (superficial and deep fibular nerve) under crossed the tendinous arch formed by the PIS and the fibularis longus and soleus muscles. The CFN was flattened in the area around the fibular head according to its very superficial course (5.5 ± 0.95 mm, range = 4–10 mm). Compression of the CFN and its main branches with resulting nerve dysfunction often occurs in this region secondarily to trauma, especially in correlation to fibrotic changes of the tendinous arch, which has been already described by Dellon et al. (2002).

A bipartition of the origin of the fibularis longus muscle was described as follows: a) the superficial portion originated from the fibular head, the anterior ligament of the fibular head, the intermuscular septa of the leg and the deep fascia of the leg; and b) the deep portion was attached to the proximal to middle third of the lateral surface of the fibula and showed a high origin from the neck of the fibula in 30 legs (27%). Consequently, the arising muscular branches of the DFN were located between these two "heads" of the fibularis longus muscle within the fibular compartment (Fig. 4). The majority of the investigated legs (73%), however, showed a division of the DFN between the superficial head of the muscle and the neck of the fibula according to the very caudal origin of the deep head of the muscle from the middle third of the fibular shaft (Table 4).

The particular muscular branches of the DFN, located between the two heads of the fibularis longus muscle, seemed to be exposed to higher compression

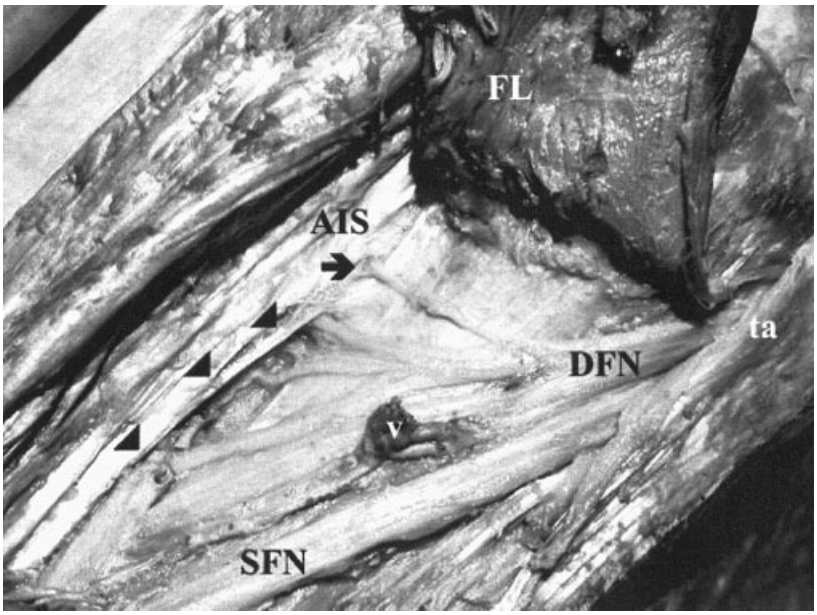

Fig. 5. Lateral aspect of a proximal left leg showing the proximal muscular branch of the deep fibular nerve (arrow) piercing the anterior intermuscular septum of the leg (AIS). The more distally located branches are running through an osteofibrous hiatus (arrowheads) formed by the AIS and the fibula. The fibularis longus muscle (FL) is reflected upwards with its origin still attached to the fibular head. DFN, deep fibular nerve; SFN, superficial fibular nerve; v, vascular pedicle to the fibularis longus muscle; ta, tendinous arch formed by the posterior intermuscular septum of the leg and fibularis longus muscle.

as muscle fibers can swell to 20 times their resting size (Fronek et al., 1987). This might explain why acute or chronic compartment syndromes are caused by elevating intramuscular pressure to a point where ischemic pain occurs (Schepsis et al., 1993).

The description of two separate origins of the fibularis longus muscle has only been mentioned by Parsons Schaeffer (1942), Reimann (1984), Bakkum et al. (1996), and Dellon et al. (2002). Some authors have additionally described variations like supernumerary fibular muscles (Gruber, 1887; Hollinshead, 1958; Alken and Arnold, 1970; Reimann, 1978, 1979; Platzer, 1991; Tillmann and Töndury, 1998).

The most proximal muscular branch of the DFN directly pierced the coarse AIS (Fig. 5). The nerve could not be removed without destroying its fibrous fixation within the AIS during the dissections. The trunk of the DFN directly pierced the septum more distally only in 5.4% of the investigated legs. According to these anchoring mechanisms, the piercing nerve structures are directly irritated by tension and pressure, e.g., occurring in case of compartment syndrome, in either the extensor or the fibular compartment of the leg. The more distally located muscular branches as well as the majority of the DFNs passed the AIS through an osteofibrous hiatus (Figs. 5–7), resulting in

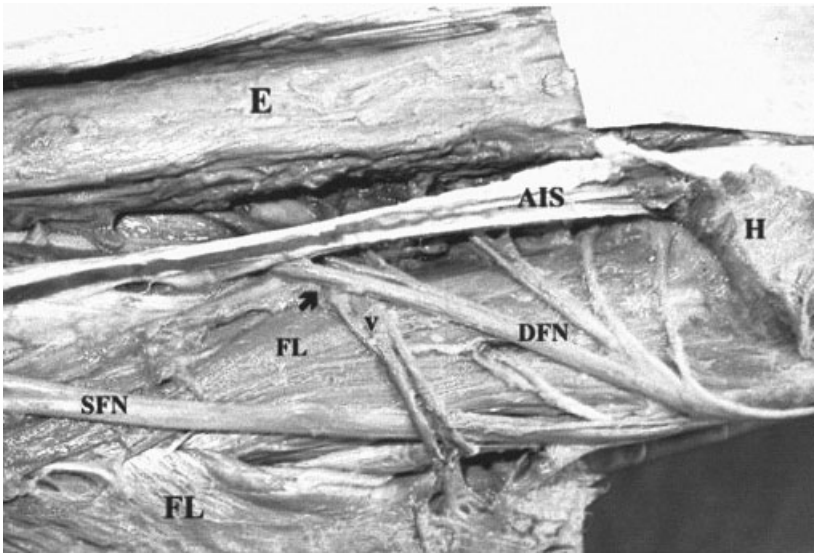

Fig. 6. Antero-lateral aspect of a proximal left leg. The vascular pedicle (v) to the fibularis longus muscle (FL) crosses deep to the DFN (arrow). AIS, anterior intermuscular septum of the leg; H, fibular head with the superficial portion of the fibularis longus muscle reflected upwards; E, extensor digitorum longus muscle; SFN, superficial fibular nerve.

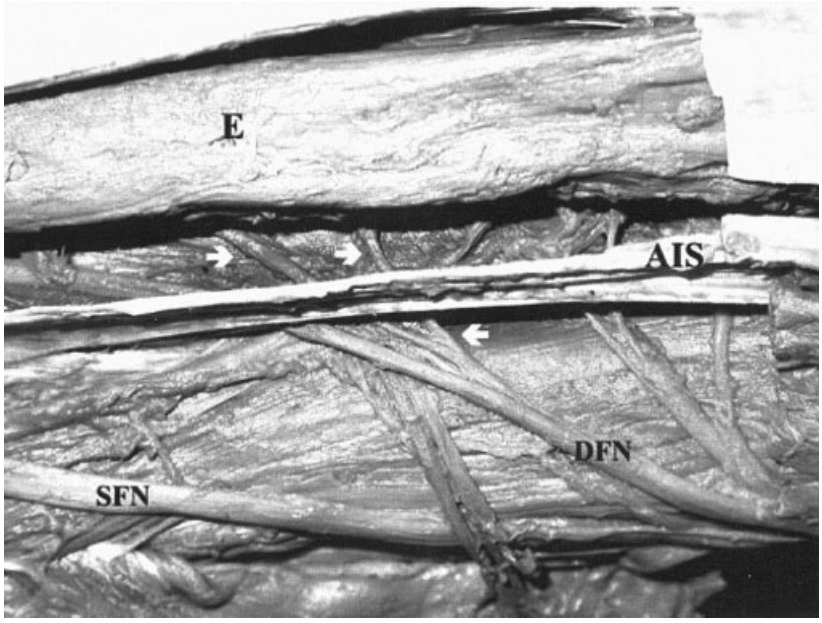

Fig. 7. Antero-lateral aspect of a proximal left leg showing the division of the trunk of the deep fibular nerve (DFN) within the fibular compartment. The terminal branches (arrows) passing the anterior intermuscular septum of the leg (AIS). E, extensor digitorum longus muscle, SFN, superficial fibular nerve.

more spacious mobility of the nerves at the level of the AIS, even though this hiatus was additionally narrowed by the deep head of the fibularis longus muscle in 24% (Table 4). In these cases, increased nerve compression should be expected.

The vascular pedicle to the fibularis longus muscle arising from the anterior tibial artery within the extensor compartment (Adachi, 1928; Lang and Wachsmuth, 1972) crossed the trunk of the DFN deep to the nerve in 15% and superficial to the nerve in 82% of the legs (Fig. 6). An increase of intramuscular pressure during compartment syndrome is also caused by diminishing venous blood flow (Schepsis et al., 1993). In consequence, it can be hypothesized that venous dilatation compresses the crossing nerves, but has not yet been proved by clinical investigation.

TABLE 4. Relationship Between the DFN and the Fibularis Longus Muscle/AIS[a]

Branching pattern of the DFN	*n* (%)	Passage of the DFN at the level of the AIS	*n* (%)
Between muscle and fibula	81 (73%)	Between AIS and fibula (osteofibrous hiatus)	78 (70.3%)
Between superficial and deep head of the muscle	30 (27%)	Between AIS and deep head of the muscle	27 (24.3%)
Total	111 (100%)		111 (100%)
Correlation between right and left leg	$P = 0.005$[b]		$P = 0.076$

[a]AIS, anterior intermuscular septum of the leg; DFN, deep fibular nerve.
[b]Correlation is significant at the 0.01 level.

We suggest that it is important for the surgeon to be aware of the areas where he has to deal with muscular branches, especially when using the AIS as a landmark during nerve reconstruction.

In summary, a clear trend could be identified with hardly significant differences between gender or right and left leg concerning the branching pattern of the DFN from a topographical point of view. Even, if the passing points of the particular branches of the DFN to the AIS showed a wide spreading in the distances from the reference point among the individual specimens (Table 3). We confirm that the neck of the fibula distally to the reference point is not a "safe area" concerning osteotomies or bone biopsies, which has been reported previously in literature (Soejima et al., 1994; Takeda et al., 2001).

The AIS can be detected easily by means of ultrasound preoperatively and seems to be an appropriate reference point and guiding structure for an intraoperative assessment of the amount of muscular branches of the DFN. Due to the wide spreading of the branches of the DFN within the fibular compartment of the leg and their inevitable closeness to the AIS, it would make sense to use the AIS as a guiding structure, when searching the nerve structures, to guarantee a safe dissection of the passing muscular branches. Additionally, the variations in the course of the fibular nerves should be taken into consideration, as they may cause some topographical confusion within the dissected region.

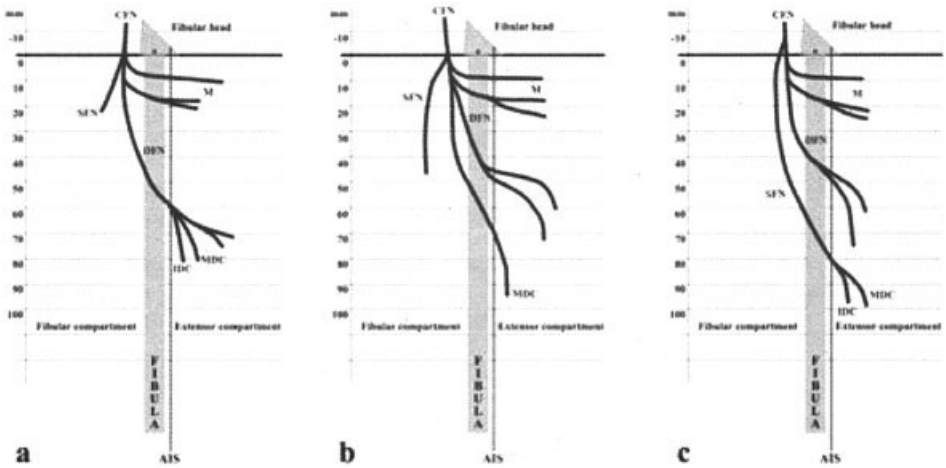

Fig. 8. Nerve variations. **A:** Intermediate (IDC) and medial dorsal cutaneous nerve (MDC) arising from the DFN. The SFN shows only M to the fibularis muscles. **B:** Accessory sensory nerve arising from the CFN. After passing the AIS, the nerve forms the MDC. **C:** SFN passing the AIS and forming the IDC and MDC within the extensor compartment. AIS, anterior intermuscular septum of the leg; CFN, common fibular nerve; DFN, deep fibular nerve; M, muscular branches of DFN; MDC, medial dorsal cutaneous nerve; SFN, superficial fibular nerve. *Reference point.

In a basic work on the ontogenetic and phylogenetic development of the antero-lateral muscles of the leg, Reimann (1983) has taken over the theories of Nussbaum (1896) and Ruge (1878b) and described two principal types of nerve variations: autogenic and myogenic varieties. Autogenic variety refers to the distribution of conventional motor and sensory fibers on non-conventional courses that can be applied to the observed variations in our study (e.g., the accessory superficial [5.4%] and deep [0.9%] fibular nerves). According to Reimann, myogenic variety means the atypical removal of muscles after fixation of the nerve-muscle relationship during later ontogenetic development (e.g., fibularis tertius muscle). The supplying area of the CFN does not change during development of the free lower limb.

Regarding the tight constitution of the muscular compartments formed by the fibrous intermuscular septa of leg, the nerve-septum relationships, as we have elucidated in this study, and the varying branching patterns of the DFN within and partly outside the fibular compartment, compressing effects on the nerves must be expected if intramuscular pressure increases (e.g., compartment syndrome). New clinical studies are required to investigate the causes of isolated muscle paralyses (e.g., by means of ultrasound) and to correlate our anatomical findings with clinical data.

REFERENCES

Adachi B. 1928. Das Arteriensystem der Japaner. Band II. Kyoto: Verlag der Kaiserlich-Japanischen Universität zu Kyoto. p 215–229.

Adkison DP, Bosse MJ, Gaccione DR, Gabriel KR. 1991. Anatomical variations in the course of the superficial peroneal nerve. J Bone Joint Surg Am 73:112–114.

Alken R, Arnold G. 1970. Ein doppelseitiger, akzessorischer Muskel der Peronaeusgruppe. Z Orthop 108:38–42.

Anson BJ. 1950. An atlas of human anatomy. Philadelphia: W.B. Saunders Company. p 450–457.

Aydogdu S, Yercan H, Saylam C, Sur H. 1996. Peroneal nerve dysfunction after high tibial osteotomy. An anatomical cadaver study. Acta Orthop Belg 62:156–160.

Bakkum BW, Russell K, Adamcryck T, Keyes M. 1996. Gross anatomic evidence of partitioning in the human fibularis longus and brevis muscles. Clin Anat 9:381–385.

Brenner E, Krimbacher E. 1995. Das Caput fibulae und seine Gelenksfläche. Z Morph Anthrop 80:281–309.

Bryce TH. 1897. Long muscular branch of the musculo-cutaneous nerve of the leg. Proc Anat Soc Great Britain and Ireland. J Anat 31:5–12.

Corning HK. 1949. Lehrbuch der Topographischen Anatomie für Studierende und Ärzte. 24th Ed. München: J.F. Bergmann. p 758–759.

Dellon AL, Ebmer J, Swier P. 2002. Anatomic variations related to decompression of the common peroneal nerve at the fibular head. Ann Plast Surg 48:30–34.

Fronek J, Mubarak SJ, Hargens AR, Lee YF, Gershuni DH, Garfin SR, Akeson WH. 1987. Management of chronic exertional anterior compartment syndrome of the lower extremity. Clin Orthop 220:217–227.

Gardner E, Gray DJ, O'Rahilly R. 1969. Anatomy. A regional study of human structure. 3rd Ed. Philadelphia: W.B. Saunders Company. p 202–204.

Gruber W. 1887. Dreibäuchiger Musculus peronaeus longus. Arch Path Anat Physiol Klin Med 109:5.

Hafferl A. 1953. Lehrbuch der Topographischen Anatomie. Berlin: Springer-Verlag. p 824–830.

Hamilton WJ. 1956. Textbook of human anatomy. London: Macmillan & Co. Ltd. p 890–897.

Healey JE, Hodge J. 1990. Surgical anatomy. 2nd Ed. Philadelphia: B.C. Decker Inc. p 292–297.

Hollinshead WH. 1958. Anatomy for surgeons: volume 3. The back and limbs. New York: Paul B. Hoeber Inc. p 821–831.

Kudoh H, Sakai T, Horiguchi M. 1999. The consistent presence of the human accessory deep peroneal nerve. J Anat 194:101–108.

Lang J, Wachsmuth W. 1972. Bein und Statik. In: von Lanz T, Wachsmuth W. Praktische Anatomie. Ein Lehr- und Hilfsbuch der Anatomischen Grundlagen Ärztlichen Handelns. 2nd Ed. Berlin: Springer-Verlag. p 309–316.

Lawrence SJ, Botte MJ. 1995. The deep peroneal nerve in the foot and ankle: an anatomic study. Foot Ankle Int 16:724–728.

Leonhardt H, Tillmann B, Zilles K. 1988. Band IV, Topographie der Organsysteme, Systematik der peripheren Leitungsbahnen. In: Rauber/Kopsch. Anatomie des Menschen. Lehrbuch und Atlas. Stuttgart: Georg Thieme Verlag. p 458–467.

Meschan I. 1975. The pelvis and lower extremity. In: an atlas of anatomy basic to radiology. Philadelphia: W.B. Saunders Co. p 167–171.

Nussbaum M. 1896. Über Muskelentwicklung. Verh Anat Ges 10:64–67.

Parsons Schaeffer J. 1942. Morris' human anatomy. A complete systematic treatise. 10th Ed. Philadelphia: The Blakiston Company. p 549–550, 1138–1142.

Peer S, Bodner G. 2003. High-resolution sonography of the peripheral nervous system. Berlin: Springer-Verlag. p 13.

Platzer W, Putz R, Poisel S. 1978. Ein neues Konservierungs- und Aufbewahrungssystem für anatomisches Material. Acta Anat 102:60–67.

Platzer W. 1991. Band I, Bewegungsapparat. 6th Ed. In: Kahle W, Leonhardt H, Platzer W. Taschenatlas der Anatomie für Studium und Praxis. Stuttgart: Georg Thieme Verlag. p 256–257.

Reimann R. 1978. Überzählige Musculi peronaei beim Menschen. Z Morph Anthrop 69:16–31.

Reimann R. 1979. Four peronei muscles in a human leg. Anat Anz 145:205–207.

Reimann R. 1983. Der laterale Bereich des Unterschenkels und des Fußrückens in funktioneller und phylogenetischer Sicht. Teil II: Funktionelles, Varietäten der Nn. Peronaei, sensible Innervation, Plexus lumbosacralis in der Evolution. Gegenbaurs morpholog. Jahrbuch 129:96–111.

Reimann R. 1984. Accessory peroneal nerves in man. Anat Anz 155:257–267.

Ruge G. 1878a. Untersuchung über die Extensorengruppe am Unterschenkel und Fuße der Säugetiere. Gegenbaurs morpholog. Jahrbuch 4:592–643.

Ruge G. 1878b. Entwicklungsvorgänge an der Muskulatur des menschlichen Fußes. Gegenbaurs morpholog. Jahrbuch 4:117–152.

Schepsis AA, Martini D, Corbett M. 1993. Surgical management of exertional compartment syndrome of the lower leg. Long-term followup. Am J Sports Med 21:811–817.

Sieglbauer F. 1963. Lehrbuch der normalen Anatomie des Menschen. 9th Ed. Wien Innsbruck: Urban & Schwarzenberg. p 671–672.

Soejima O, Ogata K, Ishinishi T, Fukahori Y, Miyauchi R. 1994. Anatomic considerations of the peroneal nerve for division of the fibula during high tibial osteotomy. Orthop Rev 23:244–247.

Takeda A, Tsuchiya H, Mori Y, Tanaka S, Kikuchi S, Tomita K. 2001. Anatomical aspects of biopsy of the proximal fibula. Int Orthop 24:335–337.

Thiel W. 1996. Photographischer Atlas der Praktischen Anatomie. Band I. Bauch, Untere Extremität. Berlin: Springer-Verlag. p 312–323.

Tillmann B, Töndury G. 1998. Band I, Bewegungsapparat. 2nd Ed. In: Rauber/Kopsch. Anatomie des Menschen. Lehrbuch und Atlas. Stuttgart: Georg Thieme Verlag. p 581–584.

Töndury G. 1949. Angewandte und Topographische Anatomie. Zürich: Fretz & Wasmuth Verlag AG. p 380–388.

Williams PL, Warwick R, Dyson M, Bannister LH. 1989. The sciatic nerve. In: Gray's anatomy. 37th Ed. New York: Churchill Livingstone. p 1145–1149.