0022-5347/95/1533-0950$03.00/0
THE JOURNAL OF UROLOGY

Vol. 153, 950-955, March 1995
Printed in U.S.A.

THE RISK OF URETHRAL TUMORS IN FEMALE BLADDER CANCER: CAN THE URETHRA BE USED FOR ORTHOTOPIC RECONSTRUCTION OF THE LOWER URINARY TRACT?

A. STENZL, H. DRAXL, B. POSCH, K. COLLESELLI, M. FALK AND G. BARTSCH

From the Departments of Urology and Biostatistics, University of Innsbruck, Innsbruck, Austria

ABSTRACT

We studied the risk of synchronous or secondary urethral tumors after long-term followup in women with bladder cancer. The charts of women treated for various stages of bladder cancer between 1973 and 1992 were reviewed. Of 356 evaluable patients 268 presented initially with primary and 78 with multilocular tumor involvement. There were 498 episodes of recurrent tumors in 127 patients, and a total 1,210 tumor locations in 854 primary and recurrent episodes of bladder cancer. Mean followup for these patients was 5.5 years (range 0.05 to 33.1). Overall 7 of 356 patients (2%) had urethral tumor involvement, all at initial presentation. Statistical comparison of various defined tumor localizations in the bladder revealed that the bladder neck ($p < 0.000$) and trigone ($p < 0.035$) were significantly more often the region of primary tumor occurrence in the urethral tumor group. All patients with secondary urethral tumors had tumor involvement of the bladder neck at the same time. A 1% urethral tumor involvement was seen among 104 patients with clinical stage T2 to 3b, N0, M0 transitional cell carcinoma, who could have been considered for curative radical cystectomy. No patient presenting with tumor recurrence regardless of its location was found to have urethral tumors. Subtotal urethrectomy is an option in select female patients after cystectomy for localized bladder cancer to allow orthotopic reconstruction of the lower urinary tract provided the bladder neck is free of tumor.

KEY WORDS: bladder neoplasms, urethral neoplasms, cystectomy

The risk of urethral tumors in men with bladder cancer has been reported in earlier series to be 4 to 18%.[1-8] Patients with carcinoma in situ and papillary or invasive tumors of the prostatic urethra are at high risk for concomitant or recurrent carcinoma of the anterior urethra after radical cystoprostatectomy. However, routine urethrectomy at the time of or shortly after cystoprostatectomy has been abandoned by most authors except in men with overt urethral tumors or those at high risk.[9,10] Sparing the urethra allows orthotopic reconstruction of the lower urinary tract with bilateral ureterointestinal urethrostomy, which at some institutions has become the urinary diversion of choice for the majority of men undergoing radical cystectomy.[9-11]

Few data exist about urethral involvement in women with bladder cancer. In the older literature, which concentrates on urethral tumor involvement in male patients with bladder cancer, female cases are rarely discussed.[8,12] In a large cystoscopy study Ashworth found urethral tumor involvement in 1.4% of female patients compared to 4.1% of male patients presenting with bladder cancer.[3] In a more recent retrospective evaluation of 22 female cystectomy specimens obtained during a 15-year period 8 cases of superficial or invasive urethral tumors were found.[13] A strong argument for routine urethrectomy in all female patients with bladder cancer was made. However, no details were provided about the total number of women treated with bladder cancer during this period, the tumor sites in the bladder and urethra or the number and type(s) of treatment before cystectomy.

We and others have demonstrated an increasing interest in performing orthotopic lower urinary reconstruction in female cystectomy patients if its function is similar to that of male patients, which would enhance the quality of life for these patients.[11,14,15] However, we need to determine if and under what circumstances a segment of the female urethra can safely be spared at cystectomy. We studied the long-term risk of secondary urethral tumors in women with bladder cancer treated at our institution between 1973 and 1992.

Accepted for publication September 9, 1994.

PATIENTS AND METHODS

The charts of women treated for bladder cancer at our hospital were reviewed. Sufficient data were available for 356 patients seen with primary or recurrent bladder tumor(s) between January 1973 and September 1992. Adequately diagnosed and documented primary tumors of recurrent bladder carcinomas, which were resected before the study period, were included, while tumors from other pelvic organs invading the bladder and 6 tumors arising primarily in the urethra were excluded.

Followup for all patients ranged from 0.05 to 33.1 years (mean 5.5, median 3.5). Transurethral biopsy and resection of the tumor were the first and only methods of treatment in 323 patients (90.7%), 21 patients (6%) received adjuvant chemotherapy or bacillus Calmette-Guerin instillation, 6 (1.7%) underwent diagnostic biopsy followed by radiation therapy and 6 (1.7%) underwent biopsy and anterior exenteration. In 12 patients subsequent radical surgery was done after repeat transurethral resection of bladder tumors. Each repeatedly treated tumor recurrence was counted as a new episode or tumor event, whereas re-resection or radiation of a subtotally resected tumor was not. There was a total of 854 episodes of primary or recurrent bladder tumors.

Mean and median patient age at initial diagnosis for all 356 evaluable patients was 68 years (range 21 to 93). The peak incidence occurred in the sixth (111 patients) and seventh (127 patients) decades. Diagnosis was transitional cell carcinoma in 332 patients (93.3%), squamous cell carcinoma in 12 (3.4%), adenocarcinoma in 10 (2.8%) and rare primary bladder tumors (1 melanoma and 1 lymphoma) in 2 (0.6%). Using the tumor, node and metastasis classification 228

cases (64%) were classified as superficial (Ta, Tis, T1) and 111 (31.2%) as invasive.[16] Among the 111 patients with invasive cancer 95 had transitional cell carcinoma, 11 had squamous cell carcinoma and 5 had adenocarcinoma. Of the patients 105 (31.8%) had grade 1 disease, 96 (29.1%) grade 2 and 129 (39.1%) grade 3 at initial diagnosis. Neither grading nor staging was done in 17 patients (4.8%). A total of 51 patients was clinically diagnosed with lymph node and/or distant metastasis (T1 in 4, T2 in 6, T3a+b in 31 and T4 in 10) and 9 patients had primary carcinoma in situ. Table 1 depicts grade for various T stages in all primary tumors regardless of histology.

Localization study. Assignment to the various regions in the bladder (that is bladder base and neck, posterior, right and left lateral walls, vault) and the urethra was done on standardized diagrams (fig. 1). Primary or recurrent and single or multiple locations were emphasized. One or several tumors in 1 region were considered to be in a single location. A large invasive solitary tumor involved 2 standard locations in 9 cases and 3 in 3. These locations were listed in the region where the bulk of the mass was presumably located. For several computations the number of separate tumor episodes (854 episodes) and the total number of 1,210 tumor locations in all 854 tumor events were used.

Statistics. Computer software was used to compute the percentages and frequencies of various subgroups. Differences between frequencies were tested using the chi-square test. For 2 × 2 tables with low minimum expected frequency we used Fisher's exact 2-tailed test.

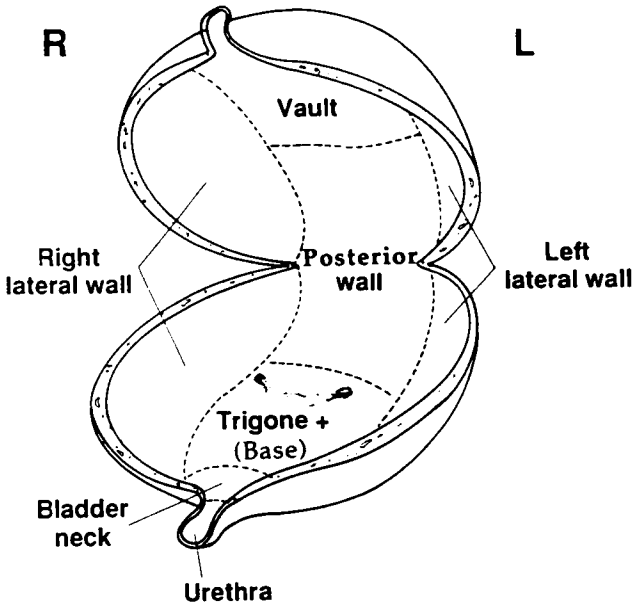

FIG. 1. Various regions of bladder to which primary or recurrent tumors were attributed.

RESULTS

Primary tumors. In 268 of the 356 women the first malignancy in the bladder tumor was solitary or at least confined to 1 of the standardized regions, whereas 78 patients (21%) initially had multiple tumors in more than 1 defined region. Data on the long-term followup with regard to tumor progression and survival will be the subject of a separate report. At initial presentation 99 patients had invasive cancer localized to the region of the bladder (T2, T3a+b), of whom 37 had nodal or distant metastases. According to the clinical staging, 62 patients would now probably have been considered as candidates for curative radical cystectomy.

Recurrent tumors. Of the 356 patients 127 (36%) had 1 or more histologically proved recurrences. Subtotal resection with subsequent palliative resection was not considered as recurrence. There were 498 episodes of recurrent tumors, including 493 (99%) in patients with transitional cell carcinoma and 5 (1%) in those with squamous cell carcinoma. None of the other patients had recurrence. Mean recurrence rate was 2.4 (range 0 to 19) for all 356 cases regardless of stage. Of 228 patients presenting initially with superficial tumor(s) 109 (48%) had at least 1 recurrence. Of the 498 recurrent tumor events 358 (71.8%) were solitary tumors or tumors confined to 1 defined region of the bladder wall, whereas 132 (26.6%) occurred in more than 1 region. There were no data available for 8 patients (1.6%).

In 405 recurrent cases (81.3%) the tumors were superficial, including 253 stage Ta (50.8%), 116 stage T1 (23.3%) and 36 stage Tis (7.2%), and 61 (12.3%) were deeply invasive, including 30 stage T2 (6.1%), 25 stage T3 (5%) and 6 stage T4 (1.2%). Data were missing in 32 patients (6.4%). In the recurrence group there was a slight shift to well differentiated tumors, consisting of 186 grade 1 (37.4%), 150 grade 2 (30.1%) and 145 grade 3 (29.1%) tumors; 17 (3.4%) were not evaluable.

TABLE 1. *Local tumor stage versus grade regardless of histology at initial presentation in 339 patients when local staging was done*

T Stage	Grade 1	Grade 2	Grade 3	Totals
Ta	78	57	12	147
T1	26	23	23	72
T2	1	12	29	42
T3	0	4	53	57
T4	0	0	12	12
Total	105	96	129	330

Carcinoma in situ in 9 cases and insufficient data in 17.

In 20 patients staging at recurrence revealed metastatic disease, including 1 with stage T1, 3 with T2, 10 with T3 and all 6 patients with T4 disease. Thus, of 127 patients with recurrent bladder tumors 42 with clinical stage T2 to 3b, N0, M0 disease would eventually have been candidates for radical cystectomy according to current criteria. When primary and recurrent localized invasive bladder cancer was combined there was a total of 104 patients in whom curative radical cystectomy with consecutive orthotopic reconstruction of the lower urinary tract might have been attempted.

Localization. Of 268 patients presenting initially with tumor(s) at a single location the majority were located at the back wall (83 patients, 31%), followed by the right (53, 19.7%) and left (68, 25.7%) lateral walls (fig. 2, *A*). A total of 12 women (4.5%) with a solitary primary tumor location initially had tumor at the bladder neck, of whom 3 (1.1%) had urethral tumors. All patients with urethral tumor involvement had tumor at the bladder neck as well. In 78 women presenting with multifocal tumors at 181 locations the back wall was again the most frequent tumor site (38 patients, 48.7%) (fig. 2, *B*). However, there was a markedly increased percentage of patients with tumors at the bladder base (34 patients, 43.6%) and bladder neck (24 patients, 32%). Four patients (5.1%) had concomitant urethral tumors, and all 4 had tumors at the bladder neck at the same time.

Among 498 recurrences 403 were unilocular (fig. 3, *A*). Most recurrences were at the posterior wall (46.7%), with considerably fewer tumors at the bladder base (7.9%) and bladder neck (6.2%), and no tumor in the urethra. There were 93 recurrences involving more than 1 bladder region and 358 localizations in these patients (fig. 3, *B*). Again, no urethral tumor could be seen in this group.

The tumor incidence in each of the defined bladder regions was statistically compared to its incidence of urethral tumor involvement. The correlation of primary tumors at the bladder neck (36 patients) and secondary urethral tumors (7 of 7

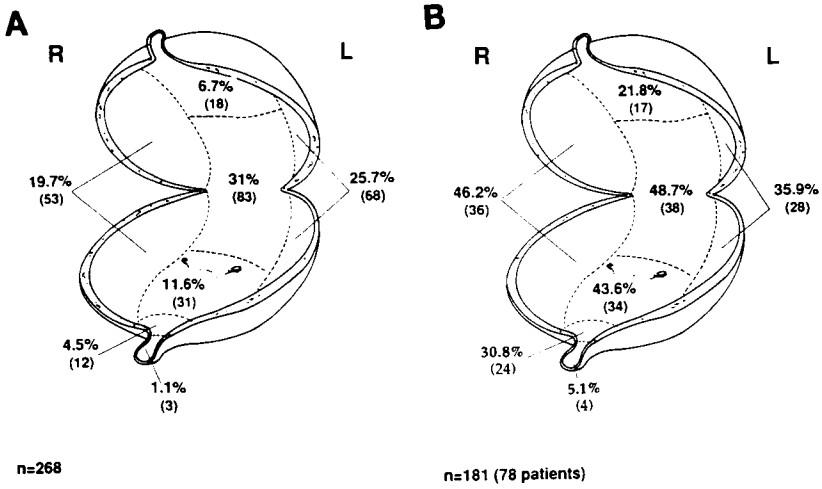

FIG. 2. *A*, distribution of unilocular bladder tumors in 268 patients at initial diagnosis. Three patients had tumors invading from bladder neck into urethra. *B*, distribution of multilocular primary tumors in 78 patients and 181 tumor locations. There were 4 tumors in urethra in 4 patients, all of whom had tumor at bladder neck simultaneously.

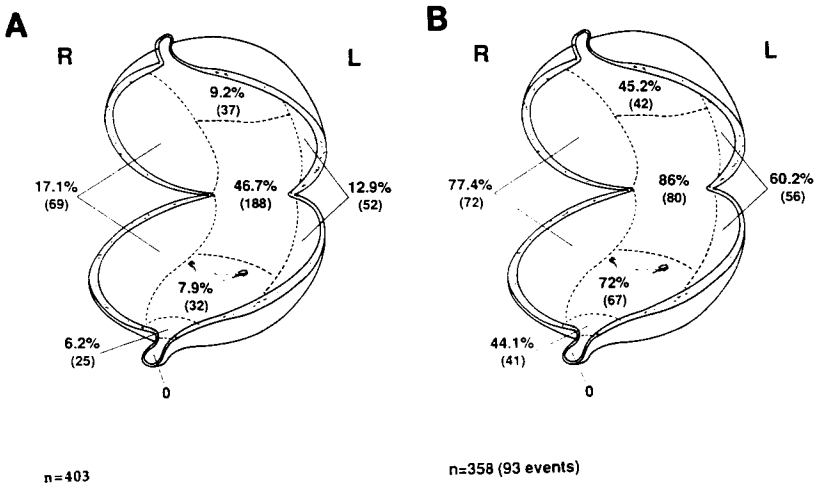

FIG. 3. Total of 498 episodes of recurrent bladder cancer was divided into 403 cases of recurrent unilocular (*A*) and 95 cases of recurrent multilocular tumors (*B*). In latter group there were 358 tumor locations. Percentages are computed from number of events, and number in parentheses denotes number of times tumor(s) was located in bladder region.

patients) was highly significant ($p = 0.000$). Tumors at the trigone (65 patients) correlated only marginally with urethral tumor involvement (4 patients, $p < 0.035$, Fisher's exact test). All other bladder regions did not correlate significantly (table 2).

The characteristics of the 7 women with urethral tumor involvement are depicted in table 3. They all had primary bladder tumors, including 5 transitional cell carcinomas. Five tumors were infiltrating and of high grade, 4 were multilocular and 3 were metastatic at diagnosis. None of the patients with transitional cell carcinoma in this group would have been a first line candidate for radical surgery either due to transurethral management or distant spread of the disease (table 3). Mean followup for these patients was 21 months (range 2 to 60). No patient in the entire study group was noted to have secondary urethral cancer more than 5 years after initial diagnosis was made.

TABLE 2. *Correlation of the location of primary bladder tumors with urethral tumor involvement in 356 patients (449 tumor locations due to solitary and multilocular tumors)*

Location	No. at Specific Location	No. Secondary Urethral Tumors (%)	p Value
Vault	35	1 (2.8)	0.77
Rt. bladder wall	89	1 (1.1)	0.51
Lt. wall	96	1 (1)	0.39
Posterior wall	121	1 (0.8)	0.18
Trigone	65	4 (6.5)	0.035
Bladder neck	36	7 (19.4)	0.000

Of 111 properly staged cases with invasive T2 to 4 cancer 96 had transitional cell carcinoma, and 3 (3.1% of all invasive transitional cell carcinoma cases) had urethral tumor involvement. Figure 4 depicts all primary and recurrent tumor locations of the study population. As in the subgroups, the back wall was the most prominent tumor site followed by both lateral walls. Of the 1,210 tumors 103 (8.5%) were located at the bladder neck, whereas urethral tumors were found in 7 cases (0.6%).

DISCUSSION

In Europe bladder cancer in women is only the fourteenth leading cause of cancer whereas it is the fifth leading cause of

TABLE 3. *Characteristics of 7 patients with primary bladder cancer and urethral tumor involvement*

Pt.	Age	Histology	Stage	Pos. or Neg. Lymph Nodes/ Metastases	Grade	Solitary Versus Multiple Tumor Locations	Location in Bladder in Addition to Urethra	Treatment Other Than Transurethral Biopsy/Resection	Followup (mos.)
MB	73	Adenoca.	T3b	Neg./neg.	3	Yes	Bladder neck	Radiation	8
GF	68	Transitional cell Ca	Ta	Neg./neg.	2	No	Vault, bladder neck	—	24
IG	63	Transitional cell Ca	T4	Pos./neg.	3	No	Lt. lateral wall, bladder neck	Radiation + chemotherapy	30
KK	87	Adenoca.	T4	No data	3	Yes	Trigone, bladder neck	Radiation	2
GK	63	Transitional cell Ca	T2	Pos./pos.	3	No	Trigone, bladder neck	Radiation	12
RP	69	Transitional cell Ca	Ta	Neg./neg.	2	No	Posterior wall, rt. lateral wall, trigone, bladder neck	—	60
IM	62	Transitional cell Ca	T3b	Neg./pos.	3	Yes	Trigone, bladder neck	Chemotherapy	14

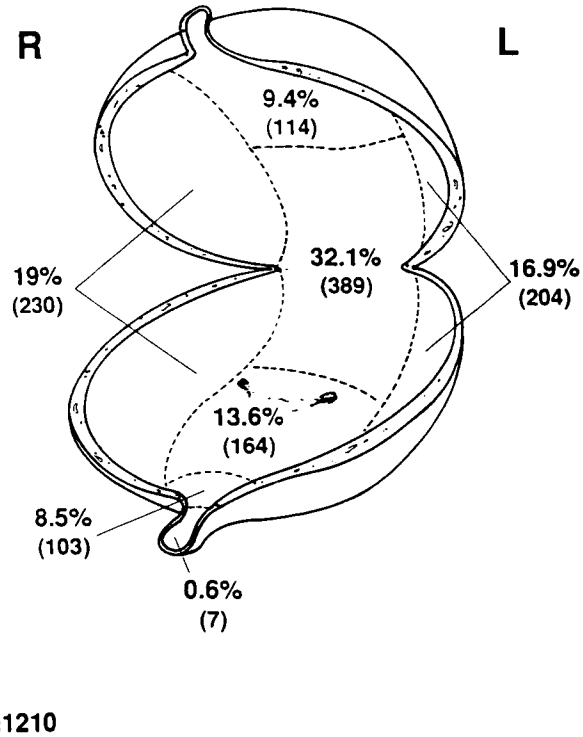

FIG. 4. Distribution of all tumor locations (1,210) in primary and recurrent tumor events. Among 1,210 tumor localizations 7 concurrent urethral tumors (0.6%) were found, all of which were in conjunction with tumor involvement of bladder neck.

cancer in men.[17] Numbers in many studies dealing with concomitant urethral tumors or urethral recurrence in patients with bladder cancer have been too small to draw any conclusions or show at least a trend for women.[1,2,6-8] However, there has recently been focused interest in data concerning the risk of secondary urethral tumors in female bladder cancer patients undergoing surgery.[18] If an adequate segment of the caudal urethra can be spared at cystectomy with a minimal risk of tumor recurrence, it may be used for continent orthotopic reconstruction of the lower urinary tract as in men.[11,14,15,19] Risk factors for urethral involvement in female bladder cancer patients are not known.

In an endoscopy study Ashworth found urethral tumors in 1.4% of 293 female patients presenting with bladder cancer in contrast to 4.1% of 1,307 male patients.[3] To our knowledge this is the only report to date of a large unselected female bladder cancer population for the study of urethral bladder tumor involvement. The result is similar to our finding of 2% urethral tumor involvement in women with biopsy proved bladder cancer of all grades and stages and with a mean followup of 5.5 years. A reason for the apparent lower incidence of secondary urethral tumors in women compared to men[4,5] may be the fact that transitional cell mucosa in women covers a much smaller urethral segment, with the remainder being normal or metaplastic squamous cell mucosa. The majority of bladder tumors (in our study population 93%) are transitional cell carcinoma. Therefore, the area at risk in the female urethra is small and probably even diminishes with increasing age because the demarcation line between squamous and transitional cell mucosa moves craniad during menopause.[20] In the sixth and seventh decades, when most of the bladder tumors occurred in our patients, metaplastic squamous cell mucosa may cover the entire urethra, bladder neck and a portion of the trigone.[20]

De Paepe et al, in a study of urethral involvement in 22 cystectomy female patients, found carcinoma in situ or overt papillary tumor in the urethra in 8 (36%) and concluded that the urethra should be removed in all women undergoing radical cystectomy for bladder cancer.[13] Unfortunately, they provided no details regarding localization of either primary tumor(s) in the bladder or secondary tumors in the urethra. We know that at least 1 patient in their series had direct extension of bladder neck tumor into the urethral wall. Their total number of 8 patients with urethral involvement seen during a 15-year period is not too different from our 7 patients seen in 20 years.

The fact that tumor involvement of the bladder neck and prostatic urethra is a possible predictor for synchronous or recurrent urethral tumors in male patients has been shown by several authors.[4,5,21] There has also been a recent report describing the close coincidence between tumor involvement of the bladder neck and urethra in women.[18] Neither in this patient group nor in our study population was there urethral bladder cancer involvement without simultaneous tumor involvement at the bladder neck. Except for a highly significant correlation between bladder neck and urethral tumor involvement ($p = 0.000$), and a marginally significant correlation between trigone and urethral tumor involvement ($p < 0.035$) none of the other bladder regions coincided significantly with secondary urethral tumors in our study (table 2). Note that all patients, regardless of the histology, had tumor at the bladder neck, whereas some with multifocal tumors had additional tumor sites at the trigone, lateral and posterior walls, and vault. We did not find any patient with recurrent bladder tumors, with or without progression, who had overt urethral tumor at any of the recurrences during followup (fig. 3).

Considering only patients with invasive localized disease (T2 to 3b, N0, M0) who would have been good candidates for radical surgical treatment, only 1 (1%) of 104 (62 with primary and 42 with recurrent tumors as described previously) had secondary urethral cancer. Among all 96 invasive (T2 to 4) transitional cell carcinoma patients 3 had urethral tumor involvement resulting in an involvement rate of 3.1% for this subgroup. A reason for the relatively small differences in the rate of urethral cancer between the overall study population and these subgroups (2% versus 1% and 3.1%, respectively)

TABLE 4. *Review of the literature with documented cases of urethral tumor involvement or carcinoma in situ in women with bladder cancer*

Reference	Study Period	No. Pts.	No. Bladder Neck Tumors	No. Urethral Tumors	Ca In Situ
Riches, E. W. and Cullen, T. H.: Brit. J. Urol., **23:** 209, 1951	Not given	19*	3	3	—
Ashworth[3]	Not given	293	Not given	4	—
Clark[12]	1964–79	Not given	Not given	2	—
Richie and Skinner[1]	1969–71	21*	Not given	—	1
Coutts et al[2]	1974–83	18*	Not given	2	1
De Paepe et al[13]	1974–88	22*	Not given	5	3
Stein et al[14]	1982–92	65*	16	7	—
Present series	1973–92	356	49	6	—
Totals		794		29	5

* Heterogeneously selected bladder cancer study populations.

might be the fact that the urethral tumor group is small and heterogeneous. The only consistent risk factor for urethral tumors in our study was tumor localized at the bladder neck at initial presentation (7 of 7 patients). Of these 7 patients 5 had grade 3 tumors but neither stage, multicentricity, number of tumors, presence of carcinoma in situ nor duration of the disease seemed to have a predominant role (table 3).

From these data one may conclude that in female patients without tumor at the bladder neck or at frozen section of the proximal urethra at cystectomy a portion of the urethra can probably be spared to enable lower urinary reconstruction to the urethra without running a greater risk of developing recurrent urethral tumors than their selected male counterparts. Therefore, we recommend several biopsies of the bladder neck in all patients when subtotal urethrectomy is considered. Any woman with atypia or overt tumor at the bladder neck is at risk of recurrent urethral tumor after cystectomy and should probably undergo simultaneous total urethrectomy. In patients for whom curative radical cystectomy is indicated and who are good candidates for orthotopic reconstruction of the lower urinary tract a segment of the urethra may be spared for that purpose provided that multiple preoperative biopsies of the bladder neck and frozen section of the urethra at the time of surgery are free of atypia or tumor.

Based on the results of this study as well as anatomical data of the continence mechanism of the female urethra,[22] we started a clinical protocol offering ureteroileal urethrostomy to carefully selected female patients undergoing radical cystectomy for localized bladder cancer if the bladder neck is free of tumor on preoperative multiple biopsies and bimanual palpation. The technique[19] and preliminary data[11,18] have been reported. However, we do not promote to leave the urethra or a portion of it unless it is used for reconstructive purposes, because it can easily be removed en bloc with the bladder specimen and it is difficult to follow when left as a blind ending sac.

Reviewing the literature we found 35 cases of documented urethral tumor involvement (including carcinoma in situ) in female patients with bladder cancer and we add 7 cases of our own (table 4). The overall incidence according to table 4 would be 4.3% (34 of 794 patients). Except for Ashworth,[3] however, all studies consisted of a highly selected group of cystectomy patients. The actual number of women seen and treated for bladder cancer at any of these institutions should have been higher. Therefore, to obtain an overall urethral involvement rate for female bladder cancer patients it is misleading to use percentages only of the total number of cystectomy patients included in these studies.

CONCLUSIONS

We have followed 356 female patients with different stages of bladder tumor for up to 33 years. The incidence of urethral tumor involvement was 2% for the entire study group, 3.1% for invasive (T2 to 4) transitional cell carcinoma and 1% for localized (T2 to 3b, N0, M0) invasive cancer amenable to radical cystectomy. The only consistent risk factor found in our study for secondary urethral cancer was simultaneous primary tumor involvement of the bladder neck. Concomitant urethral tumors were neither seen in patients with a bladder neck free of tumor nor in patients with tumor recurrences. There was no correlation between urethral cancer and any other prognostic factor. We conclude that a large segment of the urethra can safely be left in selected cystectomy female patients undergoing orthotopic urinary reconstruction to the remnant urethra, provided neither preoperative biopsies of the bladder neck nor intraoperative frozen section of the urethra at the level of dissection shows any tumor or atypia.

REFERENCES

1. Richie, J. P. and Skinner, D. G.: Carcinoma in situ of the urethra associated with bladder carcinoma: the role of urethrectomy. J. Urol., **119:** 80, 1978.
2. Coutts, A. G., Grigor, K. M. and Fowler, J. W.: Urethral dysplasia and bladder cancer in cystectomy specimens. Brit. J. Urol., **57:** 535, 1985.
3. Ashworth, A.: Papillomatosis of the urethra. Brit. J. Urol., **28:** 3, 1956.
4. Hardeman, S. W. and Soloway, M. S.: Urethral recurrence following radical cystectomy. J. Urol., **144:** 666, 1990.
5. Stöckle, M., Gökcebay, E., Riedmiller, H. and Hohenfellener, R.: Urethral tumor recurrences after radical cystoprostatectomy: the case for primary cystoprostatourethrectomy? J. Urol., **143:** 41, 1990.
6. Cordonnier, J. J. and Spjut, H. J.: Urethral occurrence of bladder carcinoma following cystectomy. J. Urol., **87:** 398, 1962.
7. Schellhammer, P. F. and Whitmore, W. F.: Transitional cell carcinoma of the urethra in men having cystectomy for bladder cancer. J. Urol., **115:** 56, 1976.
8. Gowing, N. F. C.: Urethral carcinoma associated with cancer of the bladder. Brit. J. Urol., **32:** 428, 1960.
9. Skinner, D. G., Boyd, S. D., Lieskovsky, G., Bennett, C. and Hopwood, B.: Lower urinary tract reconstruction following cystectomy: experience and results in 126 patients using the Kock ileal reservoir with bilateral ureteroileal urethrostomy. J. Urol., **146:** 756, 1991.
10. Studer, U. E., Gerber, E., Springer, J. and Zingg, E. J.: Bladder reconstruction with bowel after radical cystectomy. World J. Urol., **10:** 11, 1992.
11. Stenzl, A., Janetschek, G., Bartsch, G., Hofer, C. and Hartung, R.: Experience with the Kock ileal reservoir for reconstruction to the urethra in male and female patients. Urologe A, **33:** 9, 1994.
12. Clark, P. B.: Urethral carcinoma after cystectomy: the case for routine urethrectomy. J. d'Urol., **90:** 173, 1984.
13. De Paepe, M. E., André, R. and Mahadevia, P.: Urethral involvement in female patients with bladder cancer. A study of 22 cystectomy specimens. Cancer, **65:** 1237, 1990.
14. Stein, J., Stenzl, A., Esrig, D., Freeman, J., Boyd, S., Lieskovsky, G., Draxl, H., Janetschek, G., Bartsch, G. and Skinner, D.: Lower urinary tract reconstruction following cystectomy in the female using the Kock ileal reservoir with bilateral uret-

eroileal urethrostomy: initial experience. J. Urol., part 2, **151:** 240A, abstract 51, 1994.

15. Tobisu, K., Coloby, P. J., Fujimoto, H., Mizutani, T. and Kakizoe, T.: An ileal neobladder for a female patient after a radical cystectomy to ensure voiding from the urethra: a case report. Jap. J. Clin. Oncol., **22:** 359, 1992.
16. Harmer, M. H.: TNM classification of malignant tumours, 3rd ed. Geneva: International Union Against Cancer, 1978.
17. Jensen, O. M., Esteve, J., Møller, H. and Renard, H.: Cancer in the European community and its member states. Eur. J. Cancer, **26:** 1167, 1990.
18. Stein, J. P., Cote, R., Freeman, J. A., Esrig, D., Skinner, E. C., Boyd, S. D., Lieskovsky, G. and Skinner, D. G.: Lower urinary tract reconstruction in women following cystectomy for pelvic malignancy: a pathological review of female cystectomy specimens. J. Urol., part 2, **151:** 304A, abstract 308, 1994.
19. Stenzl, A., Colleselli, K. and Bartsch, G.: Continent reservoir to the urethra in the female. J. Urol., part 2, **151:** 204A, videotape V-19, 1994.
20. Peckham, D. A.: The epithelial lining of the female trigone and urethra. Brit. J. Urol., **43:** 201, 1971.
21. Levinson, A. D., Johnson, D. E. and Wishnow, K. I.: Indications for urethrectomy in an era of continent diversion. J. Urol., **144:** 73, 1990.
22. Colleselli, K., Strasser, H., Moriggl, B., Stenzl, A., Poisel, S. and Bartsch, G.: Hemi-Kock to the female urethra: anatomical approach to the continence mechanism of the female urethra. J. Urol., part 2, **151:** 500A, abstract 1089, 1994.