GASTROENTEROLOGY 2002;123:992–998

Appendicitis: Should Diagnostic Imaging Be Performed if the Clinical Presentation Is Highly Suggestive of the Disease?

THOMAS RETTENBACHER,* ALOIS HOLLERWEGER,† NORBERT GRITZMANN,† THADDAEUS GOTWALD,* KLAUS SCHWAMBERGER,§ HANNO ULMER,‖ and DIETER ZUR NEDDEN*

*Department of Radiology II, University Hospital Innsbruck, Innsbruck; †Department of Radiology and §Department of Surgery, Hospital Barmherzige Brueder, Salzburg; and ‖Institute of Biostatistics, University of Innsbruck, Innsbruck, Austria

Background & Aims: **Our aim was to investigate whether diagnostic imaging is required if the clinical presentation suggests acute appendicitis with high probability.** ***Methods:*** **On the basis of clinical findings, 350 consecutive patients with clinical suspicion of acute appendicitis were prospectively divided into 3 groups as follows: low, intermediate, and high probability of having appendicitis. All patients then underwent diagnostic ultrasonography. The clinical likelihood of appendicitis and the ultrasonographic results were correlated with the definite diagnoses.** ***Results:*** **In the patients with clinically low probability of having appendicitis, appendicitis was present in 10% (11 of 109 patients), and, in those with intermediate probability, appendicitis was present in 24% (23 of 97 patients). Patients with clinically high probability of having appendicitis had appendicitis in 65% (94 of 144 patients), an alternative diagnosis in 18% (26 of 144 patients), and no specific definitive diagnosis in 17% (24 of 144 patients). Ultrasonography diagnosed appendicitis and the differential diagnoses with a sensitivity of 98% and 97%, specificity of 98% and 100%, positive predictive value of 96% and 99%, negative predictive values of 99% and 99%, and accuracy of 98% and 99%, respectively.** ***Conclusions:*** **Even in patients with clinically high probability of acute appendicitis, diagnostic imaging should be performed because it accurately depicts a high percentage of normal appendices and differential diagnoses.**

Acute appendicitis is one of the most common causes of acute abdomen disorders, with at least 250,000 cases per year in the United States alone.[1,2] Diagnosis is based mainly on the clinical presentation, physical examination, and simple laboratory tests. Although the clinical symptoms are often characteristic, other disorders such as mesenteric lymphadenitis, bacterial ileocecitis, enteritis, acute diverticulitis, ureteral calculi, and pelvic inflammatory disease can mimic acute appendicitis.[1,3,4] To improve diagnostic accuracy, cross-sectional imaging modalities such as ultrasonography and computed tomography (CT) are widely used and state of the art.[1,5–14] These imaging modalities, in addition to the clinical evaluation, are of considerable value in patients with atypical presentation or equivocal clinical findings.[1,3,5–8,10–12,15–24] Several authors stated that patients with a clinically high suspicion of acute appendicitis should directly undergo appendectomy without diagnostic imaging preoperatively, but the majority of the studies did not provide sufficient data to support the assertion.[1,5,6,8,12,15,17,25–27] The present study was carried out to prospectively investigate whether cross-sectional imaging should be performed in patients with a clinically high probability of having acute appendicitis.

Materials and Methods

The study included all 350 patients (191 women, 159 men; mean age, 33 years; age range, 5–92 years) with clinical suspicion of acute appendicitis, who were admitted to the surgery department of a single hospital within a time period of 3 years. In the surgery department, the patients underwent evaluation of clinical history and physical examination, which were performed by 1 of 4 surgeons. The experience of these surgeons in abdominal surgery covered a practice period between 4 and 25 years, with a mean of 13 years. The experience of the surgeons was regarded as important because the clinical evaluation of a patient with abdominal symptoms also requires considerable experience, which can hardly be quantified. In addition, simple tests such as temperature, erythrocyte sedimentation rate, complete blood count, C-reactive protein, and urinalysis were performed. Immediately afterwards, the surgeons were requested to estimate the patients' likelihood of having acute appendicitis on the basis of clinical history, physical examination, and assessed tests. Three categories were offered, including low, intermediate, and high probability of acute appendicitis. Then, all patients were referred to an ultrasonographic examination of the appendix and the abdomen, which was performed by 1 of 4 radiologists, who were highly experienced in gastrointestinal ultrasonography. The

Abbreviations used in this paper: CT, computed tomography.

0016-5085/02/$35.00
doi:10.1053/gast.2002.35956

applied ultrasonographic criteria to discriminate an acutely inflamed appendix from a normal one included the location of the point of maximum tenderness, the outer appendiceal diameter (cutoff point for appendicitis ≥ 6 mm), the appendiceal compressibility, the hyperechoic periappendiceal fatty tissue, the appendiceal shape, the gas in the appendiceal lumen, the blood flow in the appendiceal wall detected at color Doppler sonography, and the appendoliths. The investigators were blinded to the results of the physical examination and tests but not to the patients' symptoms. Immediately after imaging, the investigators had to describe the ultrasonographic findings and had to give a clear ultrasonographic diagnosis on a prepared sheet of paper. If the appendix and/or a differential diagnosis were detectable, the ultrasonographic investigation was considered as conclusive, whereas the failure to detect the appendix and the simultaneous failure to detect a differential diagnosis were taken as an inconclusive investigation.

Ultrasonography was performed on commercially available high-quality equipment (HDI 3000 unit; Advanced Technology Laboratories, Bothell, WA and AU4 unit; Esaote, Florence, Italy) with 2–5 MHz curved-array and 5–10 MHz linear-array transducers.

The definite diagnoses were established and confirmed at surgery and histologic examination in 154 patients and at clinical follow-up in 196 patients. The histologic criteria for acute appendicitis included the accumulation of leucocytes throughout the appendiceal wall. Appendices with catarrhal or erosive inflammatory changes at histologic examination were not considered as acutely inflamed for the study. The definite diagnoses were correlated with the clinical likelihood of acute appendicitis, ultrasonographic results, patient age, and patient sex.

For statistical analysis, we calculated the sensitivity, specificity, positive predictive value, and negative predictive value of ultrasonography in diagnosing acute appendicitis and the differential diagnoses by using 2 × 2 contingency tables. For this assessment, inconclusive ultrasonographic examinations were not excluded but taken as negative results. In patients with a clinically high probability of having acute appendicitis, age-related differences regarding the percentage of patients with acute appendicitis, differential diagnoses, and normal findings were tested using the Kruskal–Wallis test, and sex-related differences were assessed using the Pearson's χ^2 test. P values less than 0.05 were considered as statistically significant. Data analyses were performed using the statistical software package SAS version 8.0 (SAS Institute, Cary, NC) for Windows (Microsoft, Redmond, CA).

Results

The surgeons found that 109 patients had a low probability, 97 patients an intermediate probability, and 144 patients a high probability of having acute appendicitis. An overview of the proportion of patients with acute appendicitis, differential diagnoses, and normal findings with regard to the clinical likelihood of acute appendicitis is shown in Figure 1 and Table 1.

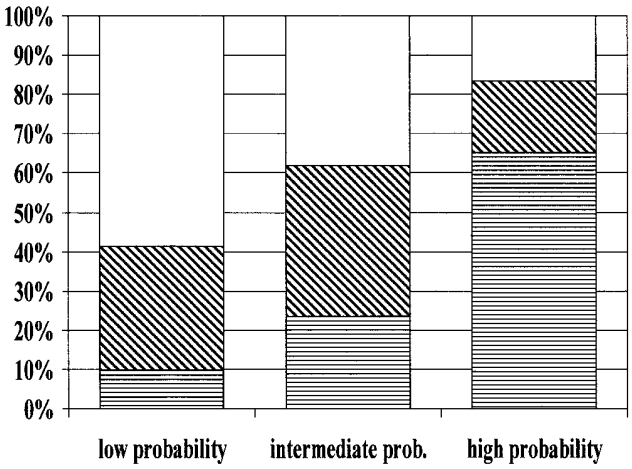

Figure 1. The proportion of definite diagnoses. *Horizontal striped* areas are for patients with acute appendicitis. *Slanted striped* areas are for patients with differential diagnoses. Empty areas are for patients with no abnormal findings. The low probability column represents 109 patients with a clinically low probability of having acute appendicitis. The intermediate probability column represents 97 patients with a clinically intermediate probability of having acute appendicitis. The high probability column represents 144 patients with a clinically high probability of having acute appendicitis. Each patient group is 100%.

Percentages and frequencies of occurrence of acute appendicitis, differential diagnoses, and normal findings in correlation with patient age are listed in Table 2. All definite diagnoses and missed diagnoses at ultrasonography in correlation to the clinical likelihood of appendicitis are listed in Table 3. Clinical information and outcome in the patients with missed diagnoses at ultrasonography are shown in Table 4.

In patients with a clinically high probability of having acute appendicitis who were aged between 15 and 45 years, female patients had acute appendicitis in 25 of 43 patients (58%), differential diagnoses in 9 of 43 patients (21%), and normal findings in 9 of 43 patients (21%), whereas male patients had acute appendicitis in 27 of 36 patients (75%), differential diagnoses in 5 of 36 patients (14%), and normal findings in 4 of 36 patients (11%). However, these differences between female and male patients were not statistically significant ($P > 0.05$).

Conclusive ultrasonographic examinations were noted in 314 of 350 patients (90%). In patients with a clinically low probability of having appendicitis, conclusive ultrasonographic examinations were present in 91 of 109 cases (83%); in patients with an intermediate probability, in 83 of 97 cases (86%); and, in patients with a high probability, in 140 of 144 patients (97%).

Table 1. Proportion of Definite Diagnoses in the 3 Patient Groups Characterized as Clinically Low, Intermediate, and High Probability of Having Acute Appendicitis in a Total of 350 Patients (Each Patient Group Is 100 Percent)

Definite diagnosis	Low probability of appendicitis, % (patients)	Intermediate probability of appendicitis, % (patients)	High probability of appendicitis, % (patients)
Acute appendicitis	10 (11/109)	24 (23/97)	65 (94/144)
Differential diagnoses	31 (34/109)	38 (37/97)	18 (26/144)
Normal findings	59 (64/109)	38 (37/97)	17 (24/144)

Inconclusive ultrasonographic examinations were noted in 36 of 350 patients (10%). There was only 1 inconclusive investigation among all 128 patients with acute appendicitis (1%) and only 4 inconclusive investigations among the 144 patients with clinically high probability of having acute appendicitis (3%). In 24 of 36 patients with an inconclusive ultrasonographic examination (67%), an additional helical CT scan was performed, which revealed acute appendicitis in 1 patient and a differential diagnosis in 1 patient. In 12 of 36 patients with an inconclusive ultrasonographic examination (33%), no additional imaging test was deemed urgent by the involved surgeon.

Ultrasonographic results were false negative in 2 of 128 patients with acute appendicitis, in 1 patient with adnexitis, in 1 patient with a ureteral stone, and in 1 patient with right-sided epiploic appendagitis (1 cm in size) (Table 3). Clinical information and outcome in each of these patients are given in Table 4.

Ultrasonography led to a false-positive interpretation of acute appendicitis in 5 patients. Sensitivity, specificity, positive predictive value, and negative predictive value of ultrasonography in diagnosing acute appendicitis and in diagnosing differential diagnoses are shown in Table 5.

The surgeons made their decision regarding treatment on the basis of the results of the conclusive ultrasonographic examinations in 310 of 314 patients (99%). One of the remaining 4 patients had acute appendicitis at surgery, and, in 3 patients, a normal appendix was removed.

In 142 of 350 patients in our study, appendectomy was performed, with 128 patients found to have acute appendicitis. In the remaining 14 patients, the surgically removed appendix was not inflamed at histologic examination, resulting in a negative appendectomy rate of 10% (14 of 142).

Discussion

The main merit of cross-sectional imaging in patients with suspicion of acute appendicitis lies largely in the ability to depict the disease in patients who present with equivocal clinical signs and where the diagnosis is therefore in doubt.[1,3,5–8,10–12,15–24] Accordingly, the results of our study showed that ultrasonography accurately helped to determine the few inflamed appendices, many normal appendices, and several differential diagnoses in patients with a clinically low and intermediate probability of acute appendicitis (Tables 1, 3, and 5). Which established imaging method, CT, ultrasonography, or both, is used largely depends on the institutional preference and experience available.[10,11,14] Several authors stated that cross-sectional imaging is not necessary if a patient clinically presents with a high suspicion of acute appendicitis.[1,5,6,8,12,15,17,25–27] However, only a few articles provided data to discuss this assertion.[3,15,17,26–28]

We identified 3 important requirements for diagnostic imaging to have an impact on the successful treatment of the patients with a clinically high probability of acute appendicitis. One was that the percentage of patients without appendicitis has to be relatively high. Another was that the imaging method used has to accurately depict acutely inflamed appendices as well as differential diagnoses. Another requirement was that the surgeons have to treat according to the imaging diagnosis if the investigation is conclusive.

Table 2. Percentages and Frequencies of Occurrence of Acute Appendicitis, Differential Diagnoses, and Normal Findings in Correlation With Patient Age in a Total of 350 Patients

Definite diagnosis	0–14 Years of age, % (patients)	15–45 Years of age, % (patients)	46–92 Years of age, % (patients)
Acute appendicitis	25.5 (13/51)	31 (63/201)	53 (52/98)
Differential diagnoses	31.5 (16/51)	29 (58/201)	23.5 (23/98)
Normal findings	43 (22/51)	40 (80/201)	23.5 (23/98)

Table 3. Definite Diagnoses in 350 Patients With a Clinically Low (n = 109), Intermediate (n = 97), and High (n = 144) Probability of Having Acute Appendicitis

Diagnoses	Low probability of appendicitis	Intermediate probability of appendicitis	High probability of appendicitis
Normal findings	64	37	24
Acute appendicitis	11	22+**1**	93+**1**
Enteritis	15	8	1
Ileitis	2	2	0
Ileocolitis	1	3	4
Colitis	3	4	1
Mesenteric adenitis	2	7	3
Acute right-sided colonic diverticulitis	0	1	5
Acute sigmoid diverticulitis	0	2	0
Carcinoma of colon	2	1	0
Incomplete ileus	1	1	0
Incarcerated hernia	1	0	0
Crohn's disease	1	0	1
Sigmoid volvulus	0	1	0
Mesenteric infarction	1	0	0
Acute cholecystitis	0	1	0
Acute inflammation of Meckel's diverticulum	0	0	1
Epiploic appendagitis	0	0	1+**1**
Ovarian cyst	3	3	1
Adnexitis	0	**1**	2
Ectopic pregnancy	0	0	1
Ureteral calculus	1	1	2+**1**
Pyelitis	1	1	0
Pyonephrosis	0	0	1

NOTE. Numbers of patients with missed diagnoses at ultrasonography are boldfaced.

The results of our study, which indicated that only 94 of 144 patients (65%) with a clinically high probability of acute appendicitis had the disease, were in accordance with a study by Schwerk et al.,[3] in which, similarly, 85 of 131 patients (65%) with a clinically high suspicion had acute appendicitis. In our opinion, such a high percentage of differential diagnoses and normal findings in that study group (Tables 1 and 3) justifies preoperative imaging. However, in 2 articles, the authors did not find preoperative imaging reasonable because of a very high prevalence of appendicitis in patients with a clinically high probability, namely 94% (109 of 116) and 90% (94 of 105), respectively.[15,17] One possible reason for the high percentages might be that they defined the patient groups as clinically unequivocal appendicitis in one study and typical presentation or high clinical probability in the other.[15,17] Nevertheless, the extraordinarily high percentage of appendicitis remains unclear in our opinion. Furthermore, they did not mention whether they encountered differential diagnoses in that patient group.[15,17]

It can be questioned whether there was a sex- and/or age-related difference in the likelihood of having acute appendicitis within the high probability group in our study, which would possibly justify defining a subgroup of patients that would not have required preoperative imaging. Especially between young adult female and male patients, a noticeable difference might be expected because of the spectrum of gynecologic disorders mim-

Table 4. Clinical Information and Outcome in the Patients With Missed Diagnoses at Ultrasonography

Patient no.	Definite diagnoses	Patient's age and sex	Symptoms and duration of symptoms before hospital admission	Ultrasonographic diagnoses	Other imaging examinations	Therapy	Time delay to adequate therapy
1	Perforated gangrenous appendicitis with abscess (2 cm in size)	49, F	Diffuse abdominal pain pronounced in the lower abdomen for 2 days	Normal appendix and ileocolitis	Next day: sonography and CT; CT diagnosis: appendicitis	Appendectomy	20 Hours
2	Phlegmonous appendicitis with fecolith	46, F	Pain in the right lower quadrant for 1 day	Normal appendix but distal portion (retrocecally located) not visible	None	Appendectomy	None
3	Adnexitis	35, F	Pain in the right lower quadrant for 1 day	Normal appendix and no differential diagnosis detectable	Gynecologist: physical examination and trans vaginal sonography	Antibiotic	None
4	Small mucocele, right-sided ureteral stone, perirenal urinoma, and hematoma	77, M	Pain in the right lower quadrant for 2 days	Appendix not detectable but appendicitis assumed because free fluid and fluid around ascending colon visible, no differential diagnosis detectable	Sonography and CT 3 days later; diagnosis: ureteral stone and perirenal urinoma and hematoma	Appendectomy, ureteral catheter 3 days later, lithotripsy 28 days later	3 Days
5	Epiploic appendagitis (1 cm in size)	40, M	Pain in the right lower quadrant for 3 days	Appendix not detectable, no differential diagnosis detectable	None	Laparotomy with removal of inflamed appendix epiploicum	None

Table 5. Sensitivity, Specificity, Positive Predictive Value, and Negative Predictive Value of Ultrasonography in Diagnosing Acute Appendicitis and in Diagnosing Differential Diagnoses in a Total of 350 Patients

	Sensitivity, % (patients)	Specificity, % (patients)	Positive predictive value, % (patients)	Negative predictive value, % (patients)
Acute appendicitis	98 (126/128)	98 (217/222)	96 (126/131)	99 (217/219)
Differential diagnoses	97 (94/97)	100 (252/253)	99 (94/95)	99 (252/255)

NOTE. For statistical analysis, inconclusive ultrasonographic examinations were taken as negative results.

icking appendicitis. Jeffrey et al.[22] stated that, in young men, the limited number of alternative diagnoses usually permits a high degree of diagnostic accuracy. In fact, the differential diagnoses are reduced by gynecologic disorders. Also, diseases such as sigmoid diverticulitis, neoplasms, and bowel ischemia are less frequent than in the elderly. However, even in young men, there are several important groups of common differential diagnoses, including inflammatory bowel diseases such as enteritis, ileocolitis, colitis, mesenteric adenitis, and acute right-sided colonic diverticulitis and urinary tract diseases such as ureteral calculi, besides various, less common conditions such as epiploic appendagitis, omental infarction, and Crohn's disease. The results of our study demonstrated that, even in young men with a clinically high probability of acute appendicitis, there was a 25% risk (9 of 36 patients) that no detectable disease or differential diagnosis was present, a percentage that, in our opinion, justifies preoperative imaging. An example for an important differential diagnosis, which usually occurs in young patients, is acute right-sided diverticulitis, a disease that is often clinically indiscernible from acute appendicitis and does not necessarily require surgical treatment.[29–31] All of our patients with acute right-sided diverticulitis (n = 6) were correctly diagnosed with ultrasonography, subsequently treated without surgery, and had an uneventful recovery. The differential diagnoses in the patients in our study with a clinically high probability of acute appendicitis (Table 3) showed that abdominal surgery was the treatment of choice in only 2 of 26 patients (8%). In addition, the differential diagnoses in that patient group included 4 patients with urinary tract diseases (15%), which would have been overlooked if diagnostic imaging had not been performed. Among the urinary tract diseases, one was a case of life-threatening pyonephrosis, in which immediate percutaneous drainage was necessary.

Another requirement was that the imaging method used must be sensitive and specific. In our study, sensitivity and specificity of imaging in diagnosing acute appendicitis and in diagnosing the differential diagnoses was at least 97% (Table 5). In the patient group with a clinically high probability of having acute appendicitis, we encountered 3 of 144 patients (2%) with a false-negative imaging result. One patient had acute appendicitis, 1 patient had a ureteral stone, and 1 patient had epiploic appendagitis. In the high probability group, we also had 3 of 144 patients (2%) in whom the appendix was falsely interpreted as acutely inflamed at ultrasonography. Despite these limitations, ultrasonography had a sufficiently high diagnostic accuracy, justifying preoperative imaging. In our experience, false-negative ultrasonographic results of appendicitis are much more relevant than false-positive results in a disease in which a relatively high rate of negative appendectomies was traditionally considered unavoidable. A relatively high rate of false-negative imaging results was one of the main reasons why diagnostic imaging was regarded as unwarranted in some studies.[15,17,26,27] Despite a relatively high percentage of differential diagnoses and normal findings in their high probability group, Schwerk et al.[3] did not mention whether cross-sectional imaging was helpful in that patient group. Similar to the studies mentioned above, this may be attributed to a relatively high rate of false-negative ultrasonographic results (12 of 131 patients).[3] In contrast, a very low rate of false-negative ultrasonographic results (1 of 143 cases) was the main reason why Chen et al.[28] found preoperative imaging useful in their high probability group.

With regard to false-negative ultrasonographic results, it is important to emphasize that, in recent years, the definition of a negative imaging result for acute appendicitis has changed markedly. From the beginning of appendiceal cross-sectional imaging until the middle 1990s, nonvisualization of the appendix was interpreted as a finding positive for a normal appendix because it was rarely detectable.[3,22,23,32] Today, as a consequence of high-detection rates of normal appendices, which are up to 62%, 78%, and 82% for ultrasonography[33–35] and up to 77%, 90%, and 97% for CT,[1,36,37] a negative imaging result is the detection of the appendix and identifying it as normal.[7,13] Today, the failure to detect the appendix and the simultaneous failure to determine a differential diagnosis should be taken as an inconclusive investiga-

tion. In the case of an inconclusive cross-sectional imaging investigation, an additional imaging modality should be applied or the surgeon should make the decision regarding treatment independent of imaging. Adhering to this procedure helps reduce the rate of false-negative imaging results and increases the surgeons' confidence in their radiologists.

Another requirement for diagnostic imaging to have an impact on the successful treatment of patients with a clinically high probability of acute appendicitis was that the surgeons have to treat the patients according to the imaging diagnoses if the investigations are conclusive. At our hospital, the surgeons relied to a high degree on the imaging results if the experienced radiologist definitely excluded appendicitis by imaging an unequivocal normal appendix and/or by detecting a clear differential diagnosis. In the case of an inconclusive investigation, the referring surgeon was subsequently informed that nothing abnormal was detectable but that the ultrasonographic result could not be entirely relied on. We would like to emphasize that caution is required, e.g., when diagnosing enteritis with cross-sectional imaging without visualization of the normal appendix because the imaging signs of enteritis, fluid excess and increased peristalsis in the small bowel, are unspecific. Acute appendicitis can induce an appearance in the small bowel of the lower abdomen that resembles enteritis. Adhering to the above-mentioned definition of a conclusive investigation, a false-negative imaging result with regard to acute appendicitis was extremely rare in our study (2 of 350 patients). Imaging did not replace a sophisticated clinical work up but was observed as a valuable aid for the surgeon if a clear diagnosis was detected. The surgeons' confidence in our imaging results did not result merely from the present study; it has slowly grown over the last 10 years because of close cooperation.

The results of our study show that, in patients with a clinically high probability of having acute appendicitis, cross-sectional imaging can be useful if each member of the diagnostic imaging staff is highly experienced in imaging the appendix and the gastrointestinal tract and is motivated and if there is continuous close cooperation with the surgeons who incorporate the imaging results into their decisions.

In summary, even in patients with a clinically high probability of acute appendicitis, cross-sectional imaging should be performed because it can accurately depict a relatively high percentage of normal appendices and/or differential diagnoses. If the appendix is detectable at ultrasonography and its appearance is normal and/or if an unequivocal differential diagnosis can be determined, treatment should be in accordance with the ultrasonographic diagnosis.

References

1. Funaki B, Grosskreutz SR, Funaki CN. Using unenhanced helical CT with enteric contrast material for suspected appendicitis in patients treated at a community hospital. AJR Am J Roentgenol 1998;171:997–1001.
2. Addiss DG, Shaffer N, Fowler BS, Tauxe RV. The epidemiology of appendicitis and appendectomy in the United States. Am J Epidemiol 1990;132:910–925.
3. Schwerk WB, Wichtrup B, Rothmund M, Rueschoff J. Ultrasonography in the diagnosis of acute appendicitis: a prospective study. Gastroenterology 1989;97:630–639.
4. Puylaert JB, Vermeijden RJ, van der Werf SD, Doorknobs L, Koumans RK. Incidence and sonographic diagnosis of bacterial ileocaecitis masquerading as appendicitis. Lancet 1989;8;2(8654): 84–86.
5. Sivit JS, Applegate KE, Stallion A, Dudgeon DL, Salvator A, Schluchter M, Berlin SC, Myers MT, Borisa VJ, Weinert DM, Morrison SC, Grisoni ER. Imaging evaluation of suspected appendicitis in a pediatric population: effectiveness of sonography versus CT. AJR Am J Roentgenol 2000;175:977–980.
6. Horton MD, Counter SF, Florence MG, Hart MJ. A prospective trial of computed tomography and ultrasonography for diagnosing appendicitis in the atypical patient. Am J Surg 2000;179:379–381.
7. Pickuth D, Heywang-Köbrunner SH, Spielmann RP. Suspected acute appendicitis: is ultrasonography or computed tomography the preferred imaging technique? Eur J Surg 2000;166:315–319.
8. Garcia Pena BM, Mandl KD, Kraus SJ, Fischer AC, Fleisher GR, Lund DP, Taylor GA. Ultrasonography and limited computed tomography in the diagnosis and management of appendicitis in children. JAMA 1999;282:1041–1046.
9. Rao PM, Rhea JT, Novelline RA, Mostafavi AA, McCabe CJ. Effect of computed tomography of the appendix on treatment of patients and use of hospital resources. N Engl J Med 1998;338: 141–146.
10. Birnbaum BA, Jeffrey RB Jr. CT and sonographic evaluation of acute right lower quadrant abdominal pain. AJR Am J Roentgenol 1998;170:361–371.
11. McColl I. More precision in diagnosing appendicitis. N Engl J Med 1998;338:190–191.
12. Birnbaum BA, Balthazar EJ. CT of appendicitis and diverticulitis. Radiol Clin North Am 1994;32:885–898.
13. Federle MP. Focused appendix CT technique: a commentary. Radiology 1997;202:20–21.
14. Jeffrey RB Jr. Questions and answers. AJR Am J Roentgenol 1995;164:1547–1550.
15. Garcia-Aguayo FJ, Gil P. Sonography in acute appendicitis: diagnostic utility and influence upon management and outcome. Eur Radiol 2000;10:1886–1893.
16. Kamel IR, Goldberg SN, Keogan MT, Rosen MP, Raptopoulos V. Right lower quadrant pain and suspected appendicitis: nonfocused appendiceal CT-review of 100 cases. Radiology 2000; 217:159–163.
17. Lessin MS, Chan M, Catollozzi M, Gilchrist BF, Richards C, Manera L, Wallach MT, Luks FI. Selective use of ultrasonography for acute appendicitis in children. Am J Surg 1999;177:193–196.
18. Galindo Gallego M, Fadrique B, Nieto MA, Callejas S, Fernandez-Acenero MJ, Ais G, Gonzalez J, Manzanares JJ. Evaluation of ultrasonography and clinical diagnostic scoring in suspected appendicitis. Br J Surg 1998;85:37–40.
19. Rao PM, Rhea JT, Novelline RA, McCabe CJ, Lawrason JN, Berger DL, Sacknoff R. Helical CT technique for the diagnosis of appendicitis: prospective evaluation of a focused appendix CT examination. Radiology 1997;202:139–144.

20. Friedland JA, Siegel MJ. CT appearance of acute appendicitis in childhood. AJR Am J Roentgenol 1997;168:439–442.
21. Quillin SP, Siegel MJ. Appendicitis: efficacy of color Doppler sonography. Radiology 1994;191:557–560.
22. Jeffrey RB Jr, Laing FC, Lewis FR. Acute appendicitis: high-resolution real-time US findings. Radiology 1987;163:11–14.
23. Puylaert JBCM. Acute appendicitis: US evaluation using graded compression. Radiology 1986;158:355–360.
24. Puylaert JBCM, Rutgers PH, Lalisang RI, DeVries BC, Van der Werf SDJ, Doerr JPJ, Blok RAPR. A prospective study of ultrasonography in the diagnosis of appendicitis. N Engl J Med 1987; 317:666–669.
25. Curtin KR, Fitzgerald SW, Nemcek AA, Hoff FL, Vogelzang RL. CT diagnosis of acute appendicitis: imaging findings. AJR Am J Roentgenol 1995;164:905–909.
26. Orr RK, Porter D, Hartmann D. Ultrasonography to evaluate adults for appendicitis: decision making based on meta-analysis and probabilistic reasoning. Acad Emerg Med 1995;2:644–650.
27. Larson JM, Peirce JC, Ellinger DM, Parish GH, Hammond DC, Ferguson CF, Verde FJ, Van der Klok HL. The validity and utility of sonography in the diagnosis of appendicitis in the community setting. AJR Am J Roentgenol 1989;153:687–691.
28. Chen SC, Chen KM, Wang SM, Chang KJ. Abdominal sonography screening of clinically diagnosed or suspected appendicitis before surgery. World J Surg 1998;22:449–452.
29. Lane MJ, Katz DS, Ross BA, Clautice-Engle TL, Mindelzun RE, Jeffrey RB Jr. Unenhanced helical CT for suspected acute appendicitis. AJR Am J Roentgenol 1997;168:405–409.
30. Jain KA, Quam JP, Ablin DS, Gerscovich EO, Shelton DK. Imaging findings in patients with right lower quadrant pain: alternative diagnoses to appendicitis. J Comput Assist Tomogr 1997;21: 693–698.
31. Chou YH, Chiou HJ, Tiu CM, Chen JD, Hsu CC, Lee CH, Lui WY, Hung GS, Yu CI. Sonography of acute right side colonic diverticulitis. Am J Surg 2001;181:122–127.
32. Balthazar EJ, Megibow AJ, Hulnick D, Gordon RB, Naidich DP, Beranbaum ER. CT of appendicitis. AJR Am J Roentgenol 1986; 147:705–710.
33. Hahn H, Hoepner F, Kalle TV, MacDonald E, Prantl F, Spitzer I, Faerber D. Appendicitis in childhood. Radiologe 1997;37:454–458.
34. Rettenbacher T, Hollerweger A, Macheiner P, Rettenbacher L, Frass R, Schneider B, Gritzmann N. Presence or absence of gas in the appendix: additional criteria to rule out or confirm acute appendicitis: evaluation with US. Radiology 2000;214:183–187.
35. Rioux M. Sonographic detection of the normal and abnormal appendix. AJR Am J Roentgenol 1992;158:773–778.
36. Lane MJ, Liu DM, Huynh MD, Jeffrey RB Jr, Mindelzun RE, Katz DS. Suspected acute appendicitis: nonenhanced helical CT in 300 consecutive patients. Radiology 1999;213:341–346.
37. Rao PM, Rhea JT, Novelline RA. Sensitivity and specificity of the individual CT signs of appendicitis: experience with 200 helical appendiceal CT examinations. J Comput Assist Tomogr 1997;21: 686–692.

Received October 26, 2001. Accepted June 27, 2002.

Address requests for reprints to: Thomas Rettenbacher, M.D., Department of Radiology II, University Hospital Innsbruck, Anichstrasse 35, 6020 Innsbruck, Austria. e-mail: thomas.rettenbacher@uklibk.ac.at; fax: (011) 43 512 504 4029.