Interactive CardioVascular and Thoracic Surgery 17 (2013) 378–383
doi:10.1093/icvts/ivt089 Advance Access publication 16 May 2013

ORIGINAL ARTICLE – ADULT CARDIAC

Simple adaptations of surgical technique to critically reduce the risk of postoperative sternal complications in patients receiving bilateral internal thoracic arteries

Adel Sakic[a], Orest Chevtchik[a], Juliane Kilo, Roland Schistek[a], Ludwig C. Mueller[a], Hanno Ulmer[b], Michael Grimm[a] and Elfriede Ruttmann[a,*]

[a] Department of Cardiac Surgery, Innsbruck Medical University, Innsbruck, Austria
[b] Department of Medical Statistics, Informatics and Health Economics, Innsbruck Medical University, Innsbruck, Austria

* Corresponding author. Department of Cardiac Surgery, Innsbruck Medical University, Anichstrasse 35, 6020 Innsbruck, Austria. Tel: +43-512-50480808; fax: +43-512-50422528; e-mail: elfriede.ruttmann@i-med.ac.at (E. ruttmann).

Received 18 September 2012; received in revised form 19 December 2012; accepted 3 January 2013

Abstract

OBJECTIVES: Limited blood supply to the thoracic chest wall is a known risk factor for sternal wound complications after CABG. Therefore, bilateral internal thoracic arteries are still rarely utilized despite their proven superior graft patency. The aim of our study was to analyse whether modification of the surgical technique is able to limit the risk of sternal wound complications in patients receiving bilateral internal thoracic artery grafting.

METHODS: All 418 non-emergent CABG patients receiving bilateral internal thoracic artery CABG procedures (BITA) from January 2001 to January 2012 were analysed for sternal wound complications. Surgical technique together with known risk factors and relevant comorbidity were analysed for their effect on the occurrence of sternal wound complications by means of multivariate logistic regression analysis.

RESULTS: Sternal wound complications occurred in 25 patients (5.9%), with a sternal dehiscence rate of 2.4% (10 patients). In multivariate analysis, diabetes (odds ratio [OR]: 4.8, 95% CI: 1.9–11.7, $P = 0.001$), but not obesity (OR: 1.6, 95% CI: 0.7–4.2, $P = 0.28$) or chronic obstructive pulmonary disease (OR: 2.2, 95% CI: 0.87–5.6, $P = 0.1$) was a relevant comorbid condition for sternal complications. Skeletonization of ITA grafts (OR: 0.17, 95% CI: 0.06–0.5, $P = 0.001$) and the augmented use of sternal wires (OR: 0.24, 95% CI: 0.06–0.95, $P = 0.04$) were highly effective in preventing sternal complications. The use of platelet-enriched-fibrin glue (PRF) sealant, however, was associated with more superficial sternal infections (OR: 3.7, 95% CI: 1.3–10.5, $P = 0.02$).

CONCLUSIONS: Adjusted for common risk factors, skeletonization of BITA grafts together with augmented sternal wires is effective in preventing sternal complications. The use of PRF sealant, however, increased the risk for superficial wound complications.

Keywords: Coronary artery bypass grafting • Bilateral internal thoracic artery • Sternal complications

INTRODUCTION

The increased risk of sternal complications has prevented a more common use of bilateral internal thoracic arteries (BITA) for coronary revascularization. However, even in spite of the accumulating evidence of the superiority of BITA regarding long-term benefit, the translation to its routine use has been minimal till now [1–3].

Most cardiac surgeons utilize the radial artery as a low-risk alternative for arterial revascularization in the hope of enhancing long-term outcome without increasing the risk of sternal complications [4]. However, in a recent clinical trial, we could demonstrate that the radial artery was not an equivalent arterial conduit to a second internal thoracic artery in terms of survival and freedom from future cardiovascular events [5]. Moreover, controlled randomized clinical trials and meta-analysis have proposed that the radial artery was not superior to saphenous vein grafts [6]. Therefore, as there are no alternative equal grafts available, the use of BITA for routine CABG procedures is warranted for the future.

The use of BITA for standard procedures of surgical revascularization should be the goal of coronary surgery; therefore, the focus in the future should be on the reduction of sternal complications to increase the safety of BITA grafting and to enable its widespread application even in high-risk patients and those of advanced age.

Therefore, the aim of our study was to investigate independent risk factors for sternal complications and analyse whether simple modification of the surgical technique is able to substantially reduce the risk of sternal complications in patients undergoing BITA grafting.

MATERIALS AND METHODS

This study analyses a consecutive series of 418 patients undergoing elective CABG using BITA from January 2001 to January 2012 at the Innsbruck Medical University. Inclusion criteria for this study were first, non-emergent isolated coronary CABG for multivessel coronary artery disease performed by a median sternotomy access and under cardiopulmonary bypass support. Furthermore, a follow-up period of at least 3 months was mandatory to be eligible for our investigation.

Surgical technique

Surgical technique and grafting strategy have not changed over the last 10 years, except for the following surgical strategies: First, we have implemented the complete skeletonized harvesting technique of ITA grafts used by most surgeons (see Fig. 1). Second, platelet-rich fibrin (PRF) glue sealant has been used as an alternative to bone wax application of the spongious parts of the chest bone. If skeletonized preparation of ITA grafts was performed, side branches were dissected by 'cold' diathermia and clipped. Furthermore, an augmented number of sternal wires and blunt instead of sharp sternal wires (size 6, either Stahldraht monofil, Ethicon, Johnson & Johnson Norderstedt, Germany or MYO/WIRE™ II sternotomy suture, Farmingdale, NY, USA) were used for parasternal wiring.

All surgeons aimed to use an *in situ* right internal thoracic artery (RITA) through the transverse sinus to graft the circumflex territories. If the RITA was too short, two different strategies were performed, but the choice was left to the preference of the surgeon, namely grafting the RITA to the left anterior descending artery (LAD) and the left internal thoracic artery (LITA) to the circumflex territory or creation of a T-graft LITA + RITA to bypass the left coronary system. Since the introduction of skeletonization, the success rate of using an *in situ* RITA through the transverse sinus tremendously increased as we are able to obtain significantly longer grafts [5]. All RA that were harvested in addition to BITA were harvested using an open surgical technique and these patients received nitrates or diltiazem for at least 3–6 months to avoid vasospasm. Complete revascularization was attempted in all cases.

PRF gel (Vivostat PRF®, Vivostat A/S, Alleroed, Denmark) was introduced in 2006 for sternal and subcutaneous application. On request, preparation of PRF was performed by the perfusionist after introduction of anaesthesia (costs per patient ~€625). From 120-ml blood, 5–6 ml of PRF were prepared and administered using the Vivostat Spraypen®.

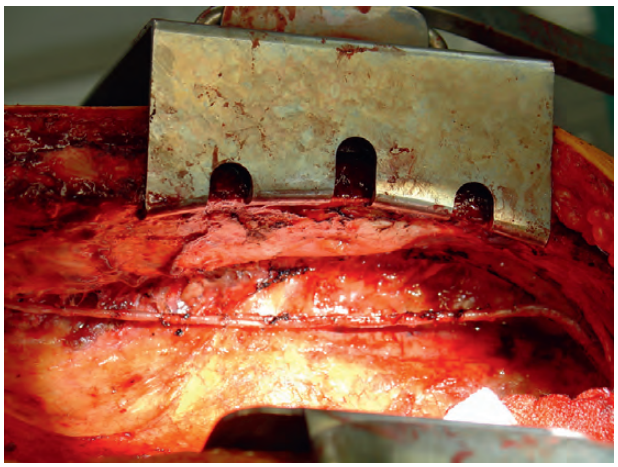

Figure 1: Fully skeletonized preparation of the internal thoracic artery.

Standard antibiotic treatment consisted of cefuroxime intraoperatively and three times daily until Day 2 or erythromycin in case of allergy to penicillin.

Definition of sternal wound complications

All sternal wound complications occurring within the first 3 months after surgery were analysed. Sternal wound complications were defined as any wound-healing disturbance requiring surgical intervention, including spreading of the sternal wound and consecutive open-wound management and secondary surgical closure, the application of vacuum-assisted closing devices and/or surgical debridement and sternal refixation or application of any reconstructive surgery including single debridement or muscle flaps.

Patient data were prospectively collected in full accordance with the standards of the Quality Control Working Group of the Austrian Society of Cardiothoracic Surgery [5]. The data acquisition included a telephone interview by a trained study nurse a month after patient discharge to obtain 30-day mortality and morbidity. Long-term follow-up was performed by telephone interviews with patients and referring cardiologists to evaluate the occurrence of sternal wound-healing complications and occurrence of angina, myocardial infarction and death from all causes and cardiac-related deaths. In patients with superficial wound infections that were treated in affiliated hospitals after discharge, the discharge reports were obtained and evaluated.

Late death was obtained from routine anniversary follow-up supplemented with the Social Security Death Index (Statistics Austria database). Permission for this study was obtained by the local Institutional Review Board.

Statistical analysis

Possible associations between the occurrence of sternal wound complications and sternal dehiscence and potentially predictive clinical features were assessed by means of univariate and multivariate analyses. To test for univariate differences in categorical variables, Pearson's χ^2 test or Fisher's exact test were applied. Continuous variables were tested by the use of Student's *t*-test or Mann–Whitney *U*-test. Multivariate logistic regression analysis was performed to determine the odds ratios (OR) and the 95% confidence intervals (CI) of potential predictors for sternal wound complications. Thereby, the selection of variables was based on univariate comparisons (entry criteria $P < 0.05$) and clinical relevance. *P*-values <0.05 were considered to indicate statistical significance. Data documentation and statistical analysis were performed using SPSS version 20.0 (Chicago, IL, USA).

RESULTS

Among 418 patients, a total of 25 (5.9%) developed sternal healing disturbances requiring surgical intervention. Ten of them (2.4%) developed sternal dehiscence with the need for surgical

ORIGINAL ARTICLE

Table 1: Characteristics of patients undergoing bilateral internal thoracic artery bypass grafting (CABG)—all sternal wound-healing complications

	No sternal wound healing complication (n = 393) patients	Sternal wound complication (n = 25) patients	P-value
Male gender	352 (89.6%)	22 (88%)	0.80
Age (years)	57.0 ± 9.8	58.5 ± 10.4	0.48
Age groups (years)			
<50	89 (22.6%)	6 (24%)	
50–55	74 (18.8%)	3 (12%)	
55–60	86 (21.9%)	5 (20%)	
60–65	60 (15.3%)	4 (16%)	
65–70	48 (12.2%)	3 (12%)	
≥70	36 (9.1%)	4 (16%)	0.75
Body mass index (kg/m^2)	27.2 ± 3.6	28.8 ± 4.3	**0.03**
Obesity (BMI ≥30 kg/m^2)	89 (22.6%)	10 (40%)	**0.048**
Smoker (active or previous)	172 (43.8%)	12 (48%)	0.68
Diabetes	73 (18.6%)	11 (44%)	**0.002**
Insulin-dependent diabetes mellitus	16 (4.1%)	4 (16%)	**0.025**
Chronic obstructive pulmonary disease (COPD)	134 (34.1%)	11 (44.0%)	0.31
COPD classification (Gold)			
Mild	79 (20.1%)	5 (20.0%)	
Moderate	51 (13.0%)	5 (20.0%)	
Severe	4 (1.0%)	1 (4.0%)	0.40
Renal function			
Normal (creatinine <1.17 mg/dl)	318 (80.9%)	22 (88%)	
Slightly elevated (1.17 to <2 mg/dl)	64 (16.3%)	2 (8%)	
Elevated (creatinine ≥2 mg/dl)	11 (2.8%)	1 (4%)	0.52
Preoperative creatinine (mg/dl)	1.2 ± 0.7	1.0 ± 0.3	**0.04**
Peripheral arterial disease	39 (9.9%)	5 (20.0%)	0.11
Cerebrovascular disease	18 (4.4%)	1 (4.0%)	0.89
Impaired left ventricular function (LVEF <48%)	82 (20.9%)	5 (20.0%)	0.92
Ejection fraction (%)	55.1 ± 10.5	54.0 ± 9.2	0.62
Number of sternal wires			
Maximum 6	171 (43.5%)	19 (76%)	
7–9	154 (39.2%)	4 (16%)	
10 or more	68 (17.3%)	2 (8%)	**0.007**
Platelet-rich fibrin glue sealant	135 (34.4%)	13 (52%)	0.07
Skeletonization of internal thoracic artery grafts	285 (72.5%)	12 (48%)	**0.009**
Revision due to bleeding	15 (3.9%)	1 (4%)	0.82
Logistic EuroSCORE	2.3 ± 2.8	2.7 ± 3.4	0.51

refixation and 2 received reconstructive surgery by means of the pectoral muscle flap.

Detailed patient characteristics are displayed in Table 1. Patients receiving BITA grafting were predominately male, irrespective of the development of sternal complications. Obesity (22.6 vs 40%, P = 0.048) and the presence of diabetes (18.6 vs 44%, P = 0.002) or insulin dependency (4.1 vs 16%, P = 0.025) were more prevalent in patients developing sternal wound complications. Preoperative creatinine was slightly lower in patients with further sternal complications (1.2 ± 0.7 vs 1.0 ± 0.3 mg/dl, P = 0.04). Other conditions such as the presence of chronic obstructive pulmonary disease (COPD), peripheral arterial disease or cerebrovascular disease were not more present in patients developing sternal complications. Regarding surgical technique, sternal wound complications were less frequent in patients receiving more sternal wires (P = 0.007) and in patients receiving skeletonized ITA grafts (P = 0.009). PRF sealant, however, was more often (but not significantly) applied in patients with later sternal complications (34.3 vs 52%, P = 0.07). Re-exploration due to bleeding was not different between groups (P = 0.82).

Evaluation of independent predictors for sternal complications

Table 2 shows the results of the multivariate statistical analysis. After multivariate adjustment, risk factors such as obesity (Wald: 1.2, OR: 1.6, 95% CI: 0.7–4.2, P = 0.28) or COPD (Wald: 2.8, OR: 2.2, 95% CI: 0.87–5.6, P = 0.1) were not predictive of the development of sternal wound complications.

Diabetes was still a strong predictor of further sternal complications (Wald: 11.7, OR: 4.8, 95% CI: 0.87–5.6, P = 0.001). However, modification of the surgical technique could significantly reduce sternal complications. Skeletonization of both ITA grafts was the most preventive strategy to lower the risk of sternal complications (Wald: 10.5, OR: 0.17, 95% CI: 0.06–0.5, P = 0.001). The augmented use of sternal wires had an additional preventive effect on sternal complications (Wald: 4.1, OR: 0.24, 95% CI: 0.06–0.95, P = 0.04). Conversely, the application of PRF glue was associated with a higher rate of wound complications (mainly superficial) with the need for surgical intervention (Wald: 6.2, OR: 3.7, 95% CI: 1.3–10.5, P = 0.02).

Table 2: Multivariate logistic regression analysis—all sternal wound complications

	Wald	Odds ratio	95% Confidence interval	*P*-value
Skeletonized preparation of internal thoracic artery grafts	**10.5**	**0.17**	**0.06–0.5**	**0.001**
Augmented sternal wire use (class)	**4.1**	**0.24**	**0.06–0.95**	**0.04**
Platelet-rich fibrin glue sealant	**6.2**	**3.7**	**1.3–10.5**	**0.02**
Obesity	1.2	1.6	0.7–4.2	0.28
Diabetes	**11.7**	**4.8**	**1.9–11.7**	**0.001**
Chronic obstructive pulmonary disease	2.8	2.2	0.87–5.6	0.1

DISCUSSION

The result of our study has clearly shown that simple changes of surgical technique can significantly reduce sternal wound complications after BITA grafting. Fully skeletonized preparation of both ITA grafts had two positive effects: first, the significant reduction of sternal wound-healing complications and dehiscence; second, the resulting longer RITA graft enabled more successful performance of *in situ* RITA grafting through the transverse sinus instead of excessive composite T-grafting with its shortcoming of competitive flow in low-grade stenosis [5, 7].

Furthermore, another study by Ura *et al*. has shown that the *in situ* configurations of both ITAs demonstrated the highest patency rates and a 94% success rate of grafting the targeted circumflex branch as *in situ* graft, supporting its continuous widespread application [8, 9].

Deep sternal wound infection has been declared a 'quality-of-care' criterion by the Society of Thoracic Surgeons; therefore, BITA grafting is rarely performed in the USA. However, decreasing rates of sternal complications during the past decade have not resulted in an increase in BITA utilization [3]. The beneficial effect of skeletonized ITA harvesting has been shown in previous studies on single ITA grafting. In concordance with our results, Saso *et al*. concluded a significant reduction of sternal complications in CABG patients, in the diabetic subgroup the reduction of sternal complications was even higher [10]. Furthermore, in a prospective randomized within-patient comparison, skeletonization of ITA reduced postoperative pain and dysaesthesia and significantly improved the sternal perfusion without increasing the vasoreactivity of skeletonized grafts [11].

Currently, the superiority of either pedicled or skeletonized ITA grafts regarding long-term patency has never been investigated; observational studies, however, show convincing long-term results of both preparation techniques [12, 13].

Sternal complications mainly develop from the distal third of the sternal region, being the most ischaemic area after ITA harvesting and therefore an ideal acid ambience for bacteria (predominately staphylococcus) to grow [14].

Our study has clearly shown that the augmented use of sternal wires added to the mechanical stability of the chest wall resulting in a lower incidence of sternal complications. Till now, evidence has been lacking on the number of sternal wires needed for the holding power of the sternum. This fact, however, may play a key role in the prevention of mechanical and infectious complications of the sternal wound. Friberg *et al*. [15] concluded, in a study among 2000 cardiac surgery patients, that the use of more than six sternal wires was protective to avoid deep sternal wound infection. As a limitation, however, only <1% of patients received BITA, and there was no information about pedicled or skeletonized preparation of the ITA grafts. Additionally, another study supporting the impact of more sternal wires did not provide special information about the high-risk subgroup of CABG patients [16].

More recently, new tools for sternal closure have been established [17–19]. However, studies on the superiority of these devices for primary chest closure are still missing. The additional costs, especially for thermo-reactive clips and transverse plates, are further limitations of these new devices which might therefore not become widely used for primary chest closure.

Another approach consists of the external support of the chest wall by a newly designed support vest [20]. Wide clinical application, however, may be limited by the compliance of the patient in wearing such a device for the first few weeks after surgery.

The results of our study have clearly shown that the augmented use of sternal wires had an independent protective effect on the prevention of sternal complications due to improved mechanical stability. Conversely, the use of costly PRF glue sealant instead of bone wax was associated with a higher risk of superficial wound infections.

The use of PRF in surgical wounds has been reported previously. A study conducted on saphenectomy sites found no clinically relevant differences between PRF and the control group, either during the primary clinical stay, or in the follow-up period [21]. Another meta-analysis concluded that there was a complete healing of chronic wounds. The meta-analysis of acute wounds with primary closure studies demonstrated that the presence of infection was reduced in platelet-rich plasma-treated wounds [22]. However, both groups consisted of very heterogeneous wound sites and ulcers. Contrarily to these results, the application of PRF sealant on the spongious parts of the sternum and subcutaneous tissue was associated with a higher risk of superficial sternal wound infection.

Without early and effective treatment including antibiotics and the application of VACs, most infections result in sternal instability and deeper mediastinal infections requiring sternal refixation and extensive debridement [23].

Owing to the prospective documentation with retrospective follow-up, however, there are several limitations that need to be mentioned. Furthermore, we cannot fully eliminate possible confounders by missing covariates.

The improved long-term patency of arterial grafts, especially the second internal thoracic artery, however, may extend survival benefit even in patients at high risk of sternal complications.

Our study has clearly shown that simple and cost-effective modifications of the surgical technique are able to reduce sternal complications even in high-risk patients independently of additional risk factors.

Therefore, considering simple surgical modifications may extend the benefit of BITA grafting to a larger patient population.

Conflict of interest: none declared.

REFERENCES

[1] Lytle BW, Blackstone EH, Loop FD, Houghtaling PL, Arnold JH, Akhrass R *et al*. Two internal thoracic arteries are better than one. J Thorac Cardiovasc Surg 1999;117:855–72.

[2] Rankin JS, Tuttle RH, Wechsler AS, Teichmann TL, Glower DD, Califf RM. Techniques and benefits of multiple internal mammary artery bypass at 20 years of follow-up. Ann Thorac Surg 2007;83:1008–15.

[3] ElBardissi AW, Aranki SF, Sheng S, O'Brian SM, Greenberg CC, Gammie JS. Trends in isolated coronary artery bypass grafting: an analysis of the Society of Thoracic Surgeons adult cardiac surgery database. J Thorac Cardiovasc Surg 2012;143:273–81.

[4] Tranbaugh RF, Dimitrova KR, Friedmann P, Geller CM, Harris LJ, Stelzer P *et al*. Radial artery conduits improve long-term survival after coronary artery bypass grafting. Ann Thorac Surg 2010;90:1165–72.

[5] Ruttmann E, Fischler N, Sakic A, Chevtchik O, Alber H, Schistek R *et al*. Second internal thoracic artery versus radial artery in coronary artery bypass grafting: a long term, propensity score-matched follow-up study. Circulation 2011;124:1321–9.

[6] Benedetto U, Angeloni E, Refice S, Sinatra R. Radial artery versus saphenous vein graft patency: meta-analysis of randomized controlled trials. J Thorac Cardiovasc Surg 2010;139:229–31.

[7] Pevni D, Hertz I, Medalion B, Kramer A, Paz Y, Uretzky G *et al*. Angiographic evidence for reduced graft patency due to competitive flow in composite arterial T-grafts. J Thorac Cardiovasc Surg 2007;133:1220–5.

[8] Ura M, Sakata R, Nakayama Y, Arai Y, Saito T. Long-term patency rate of right internal thoracic artery bypass via the transverse sinus. Circulation 1998;98:2043–8.

[9] Ura M, Sakata R, Nakayama Y, Arai Y, Oshima S, Noda K *et al*. Technical aspects and outcome of in situ right internal thoracic artery grafting to the major branches of the circumflex artery via the transverse sinus. Ann Thorac Surg 2001;7:1485–90.

[10] Saso S, James D, Vecht JA, Kidher E, Kokotsakis J, Malinovski V *et al*. Effect of skeletonization of the internal thoracic artery for coronary revascularization on the incidence of sternal wound infection. Ann Thorac Surg 2010;89:661–70.

[11] Boodhwani M, Lam BK, Nathan HJ, Mesana TG, Ruel M, Zeng W *et al*. Skeletonized internal thoracic artery harvest reduces pain and dysthesia and improves sternal perfusion after coronary artery bypass surgery: a randomized, double-blind, within-patient comparison. Circulation 2006; 114:766–73.

[12] De Paulis R, de Notoris S, Scaffa R, Nardella S, Zeitani J, Del Giudice C *et al*. The effect of bilateral internal thoracic artery harvesting on superficial and deep sternal infection: the role of skeletonization. J Thorac Cardiovasc Surg 2005;129:536–43.

[13] Ali E, Saso S, Ashrafian H, Athanasiou T. Does the skeletonized or pedicled left internal thoracic artery give the best graft patency? Interact CardioVasc Thorac Surg 2010;10:97–104.

[14] Zhou ZH, Yi QF, Ling YL, Zhou JN, Liu LH, Liu XP. Mineralization and osteoblast response to bioactive glass I vitro. J Med Eng Technol 2010; 34:285–90.

[15] Friberg Ö, Dahlin LG, Söderquist B, Källman J, Svedjeholm R. Influence of more sternal fixation wires on the incidence of deep sternal wound infection. Thorac Cardiovasc Surg 2006;54:468–73.

[16] Kamiya H, Al-maisary SSA, Akhyari P, Ruhparwar A, Kallenbach K, Lichtenberg A *et al*. The number of wires for sternal closure has a significant influence on sternal complications in high-risk patients. Interact CardioVasc Thorac Surg 2012;15:1–6.

[17] Song DH, Lohman RF, Renucci JD, Jeevandam V, Raman J. Primary sternal plating in high-risk patients prevents mediastinitis. Eur J Cardiothorac Surg 2004;26:367–72.

[18] Negri A, Manfredi J, Terrini A, Rodella G, Bisleri G, El Quarra S *et al*. Prospective evaluation of a new sternal closure method with thermoreactive clips. Eur J Cardiothorac Surg 2002;22:571–5.

[19] Voss B, Bauernschmitt R, Will A, Krane M, Kröss R, Brockmann G *et al*. Sternal reconstruction with titanium plates in complicated sternal dehiscence. Eur J Cardiothorac Surg 2008;34:139–45.

[20] Gorlitzer M, Folkmann S, Meinhart J, Poslussny P, Thalmann M, Weiss G *et al*. A newly designed thorax support vest prevents sternum instability after median sternotomy. Eur J Cardiothorac Surg 2009;36: 335–9.

[21] Buchwald D, Kaltschmidt C, Haardt H, Laczkovics A, Reber D. Autologous platelet gel fails to show beneficial effects on wound healing after saphenectomy in CABG surgery. J Extra Corpor Technol 2008;40: 196–202.

[22] Carter MJ, Fylling CP, Parnell LK. Use of platelet rich plasma gel on wound healing: a systematic review and meta-analysis. Eplasty 2011;11:e38.

[23] Fleck T, Moidl R, Giovanoli P, Aszmann O, Bartunek A, Blacky A *et al*. A conclusion from the first 125 patients treated with the vacuum assisted closure system for postoperative sternal wound infection. Interact CardioVasc Thorac Surg 2006;2:145–8.

eComment. Prevention of sternal wound infection

Authors: ***Jamil Hajj-Chahine, Christophe Jayle, Paul Menu and Pierre Corbi***

Department of Cardio-Thoracic Surgery, University Hospital of Poitiers, Poitiers, France

doi:10.1093/icvts/ivt275

We read with great interest the article by Sakic *et al.* [1] assessing the efficacy of surgical modifications on the incidence of postoperative sternal complications after bilateral internal thoracic arteries (BITA) harvesting. In this single-center retrospective study, the authors demonstrated that using a skeletonized approach in patients receiving bilateral internal thoracic arteries with augmented sternal wires is effective in preventing sternal wound complications. As described by others, this series supports the claim that the risk of sternal infection can be reduced by performing internal thoracic artery harvested in a skeletonized manner. Deo *et al.* [2] conducted the first systematic review and meta-analysis to address the essential clinical question of whether BITA increases the risk of deep sternal wound infection in patients with diabetes; they concluded that the risk may be minimized using a skeletonized approach.

The left internal thoracic artery to left anterior descending artery graft has long been established as the cornerstone of improved early and late outcomes in surgically-treated patients. An overwhelming wealth of evidence, mainly retrospective studies, demonstrated that the use of BITA as bypass grafts provided superior early survival and better event-free survival after coronary artery bypass grafting. The Arterial Revascularization Trial [3] is the only randomized study comparing the outcomes of single internal mammary artery (SITA) vs BITA, with a primary outcome of survival at 10 years, and results should be available in five years. The risk of sternal wound complications may need to be weighed against the long-term benefit of BITA grafts. It is, needless to say, that anterior mediastinitis is a rare but ominous complication after BITA harvesting, carrying a high risk of in-hospital mortality.

Many factors have been suggested as responsible for postcardiotomy sternal wound infection, and investigations to prevent this dreaded complication are still considered as a greatly researched topic in cardiac surgery. Recently, Grauhan *et al.* [4] investigated the efficacy of a new commercially available negative pressure wound therapy system (Prevena Incision Management System; KCI, San Antonio, USA) as a dressing treatment to prevent sternal wound infection in obese patients undergoing cardiac surgery. They showed in a prospective study that the application of a special foam as a wound dressing immediately after skin closure and negative pressure of -125 mmHg for the first 6 to 7 days postoperatively significantly reduces the incidence of sternal infection in this high-risk patient population.

The technique of skeletonization during BITA harvest preserves sternal microcirculation [5]; the immediate application of a negative-pressure wound dressing after suturing prevents the breakdown of skin sutures and seepage of bacteria into the deeper layers. These two different methods showed to be effective in reducing the likelihood of sternal wound infection, and should be considered in high-risk patients of sternal complications.

Conflict of interest: none declared.

References

[1] Sakic A, Chevtchik O, Kilo J, Schistek R, Mueller LC, Ulmer H *et al*. Simple adaptations of surgical technique to critically reduce the risk of postoperative sternal complications in patients receiving bilateral internal thoracic arteries. Interact CardioVasc Thorac Surg 2013;17:378–83.