Original Paper · Travail original · Originalarbeit

Ophthalmologica 1995;209:60–63

B. G. Kremser[a]
M. Falk[b]
G. F. Kieselbach[a]

[a] Universitätsklinik für Augenheilkunde und
[b] Institut für Biostatistik der Universität Innsbruck, Österreich

Influence of Serum Lipid Fractions on the Course of Diabetic Macular Edema after Photocoagulation

Key Words
Macular edema
Photocoagulation treatment
Serum lipid fractions
Cholesterol
High-density lipoprotein
Low-density Lipoprotein

Abstract
The influence of serum lipid fractions [triglyceride, cholesterol, high-density lipoprotein (HDL) cholesterol, low-density lipoprotein (LDL) cholesterol] on the visual outcome after central laser photocoagulation of 39 patients (65 eyes) with clinically significant macular edema was investigated in a prospective study. Referring to normal Austrian serum lipid levels, the patients were classified into a normal and a pathological group for each of the 4 lipids. Concerning triglycerides and HDL cholesterol, the normal group (triglyceride <2.29 mmol/l, HDL cholesterol >1.3 mmol/l) showed a statistically significantly better visual outcome than the pathological group. Also, patients with normal total cholesterol and LDL cholesterol values tended to achieve better results after treatment. We therefore conclude that serum lipid fractions may influence not only the success of laser treatment but also the corse of diabetic macular edema.

Introduction

Diabetic macular edema is the most frequent cause of visual impairment in patients with non proliferative diabetic retinopathy in the 20- to 60-year age group [1]. The Early Treatment Diabetic Retinopathy Study (ETDRS) showed the benefit of photocoagulation treatment for clinically significant macular edema [2, 3]. Olk [4] even demonstrated a significant improvement of visual acuity in patients with diffuse diabetic macular edema after modified grid photocoagulation. Our own studies and clinical observation have confirmed these findings [5, 6]. However, it has been shown that patients with similar degrees of diabetic macular edema undergoing grid photocoagulation following the recommendations of the ETDRS [2, 3] present differing visual outcome values upon being treated by laser. Systolic blood pressure [7] and blood glucose [8, 9] have been reported earlier to be important influences on the progress of diabetic retinopathy. Due to the finding that regression of retinal hard exudates could be observed after normalization of lipid metabolism, we investigated the role of serum lipid fractions [triglycerides, total cholesterol, high-density lipoprotein (HDL) cholesterol, low-density lipoprotein (LDL) cholesterol] on the course of diabetic macular edema after photocoagulation treatment. The success of laser treatment does not allow a comparative randomized study of the normal course of diabetic macular edema under observation of serum lipid factors.

Received:
September 26, 1994
Accepted:
October 28, 1994

G. F. Kieselbach, MD
Universitätsklinik für Augenheilkunde
Anichstrasse 35
A–6020 Innsbruck (Österreich)

0030–3755/95/2092–0060
$8.00/0

Patients and Methods

Sixty-five eyes of 39 patients with a diagnosis of type 1 or type 2 diabetes mellitus with clinically significant circinate macular edema were observed for 12 months. Patients with cystoid or ischemic macular edema were not entered into the study. Baseline examination included optimized visual acuity, slitlamp biomicroscopy, stereo fundus photography, fluorescein angiography and the measurement of blood glucose, glycosylated hemoglobin, blood pressure and serum lipid fractions (triglycerides, total cholesterol, HDL cholesterol, LDL cholesterol), the last being taken 3 h after lunch. The average age was 60 years (spanning the interval from 34 to 78 years); 24 (62%) were female, 15 (38%) male. Thirty-two (82%) suffered from type 2 and 7 (18%) from type 1 diabetes. Thirty-one (80%) were treated by insulin, 8 (20%) by oral antidiabetic therapy. Mean initial visual acuity was 0.5 – ranging from 0.04 to 1.2 – using the Snellen chart (fig. 1, table 1). Exclusion criteria were visual acuity below 10/100, untreated hypertension, glaucoma, signs of age-related macular degeneration, myopia higher than 3 dpt, or a history of laser treatment or retinal surgery. Patients with proliferative diabetic retinopathy were not eligible for the study either but were transferred to scatter photocoagulation after treatment of maculopathy. Patients with blood pressure higher than 140/90 mm Hg or elevated blood glucose levels were put onto internal therapy before being integrated into the study. Twenty (50%) of our patients received antihypertensive medication to normalize blood pressure. Patients with levels of glycosylated hemoglobin higher than 8% (measured with the MEIA IMx-ELISA test) were excluded. Each patient received argon green grid photocoagulation according to the recommendations of the ETDRS [2, 3] within 1 week after the initial examination. Laser treatment was performed after fluorescein angiography or scanning laser ophthalmoscopy. The first check was made 12 weeks after the initial treatment. The arithmetic mean of the results of two examinations of the normal and pathological subjects in each lipid group was taken. The WHO recommended levels were 5.18 mmol/l for total cholesterol, 1.3 mmol/l for HDL cholesterol, 4.14 mmol/l for LDL cholesterol and 2.29 mmol/l for triglycerides, therefore the normal group for total cholesterol consisted of 12, for HDL cholesterol of 23, for LDL cholesterol of 30 and for triglycerides of 17 patients. Twenty-seven patients for cholesterol, 16 for HDL, 9 for LDL and 22 for triglycerides formed the pathological groups. None of our patients received any kind of lipid-lowering therapy before or during the study. Visual outcome after laser treatment of the normal and the pathological groups for each lipid fraction was compared using the matched Student's t test (two-group/unpaired/two-tail). The correlation (Pearson correlation coefficient) between Δ visual acuity and the 4 serum lipid parameters was calculated. All statistical analyses were performed with the programm Stat View® on Macintosh computers. Written consent was obtained from all study patients.

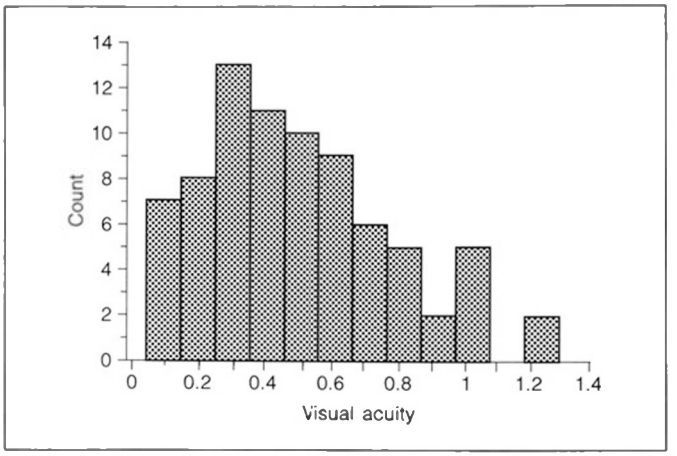

Fig. 1. Frequency distribution of visual acuities at the baseline examination in a bar chart. The mean value is 0.5.

Table 1. Frequency distribution of baseline visual acuities

Bar	From (≥)	To (<)	Count	Percent
1	0.04	0.145	7	8.974
2	0.145	0.25	8	10.256
3	0.25	0.355	13	16.667
4	0.355	0.46	11	14.103
5	0.46	0.565	10	12.821
6	0.565	0.67	9	11.538
7	0.67	0.775	6	7.692
8	0.775	0.88	5	6.41
9	0.88	0.985	2	2.564
10	0.985	1.09	5	6.41
11	1.09	1.195	0	0
12	1.195	1.3	2	2.564

'Bar' refers to the bars depicted in figure 1.

Results

The visual outcome of our patients as observed 3–4 months after treatment is shown in figures 2–5. For triglycerides, we found a statistically significant ($T = 2.97$; $p = 0.0043$) better visual outcome 3–4 months after photocoagulation treatment in the normal group (triglycerides <2.29 mmol/l) compared with the pathological group (triglycerides >2.29 mmol/l). We noticed a correlation between higher blood triglycerides and poorer visual outcome after laser treatment ($R = -0.31$; $p = 0.0123$). Also for HDL cholesterol, statistically significant ($T = 4.13$; $p = 0.0001$) better effects of photocoagulation treatment could be observed in patients of the normal group (HDL cholesterol >1.3 mmol/l) than in those of the pathological group (HDL cholesterol <1.3 mmol/l). A correlation ($R = 0.39$; $p = 0.0014$) between a lower HDL cholesterol level and poorer results of laser therapy confirmed our findings. Total cholesterol as well as LDL cholesterol also tended to be higher in cases of poorer visual outcome, but the differences between the normal and the pathological groups were not statistically significant.

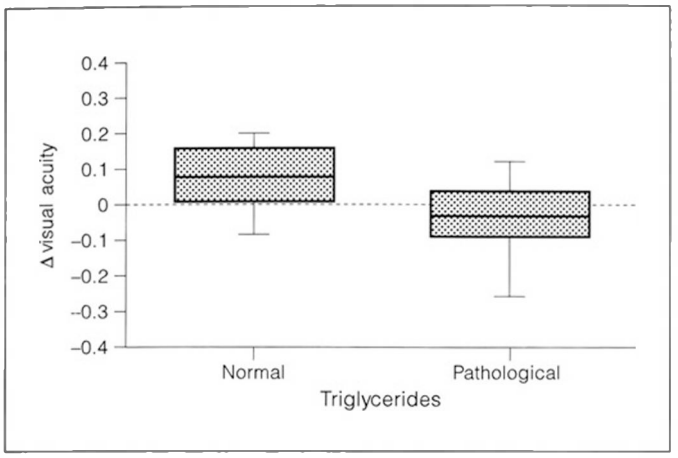

2

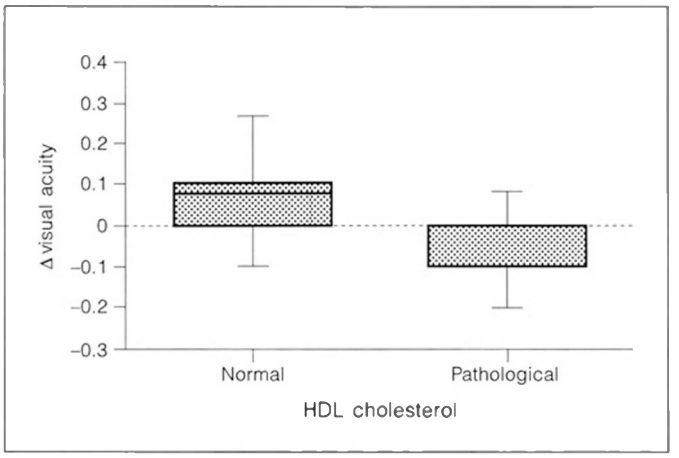

4

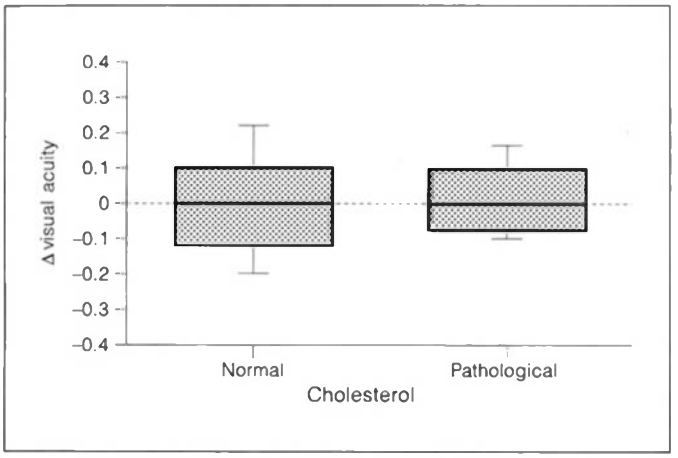

3

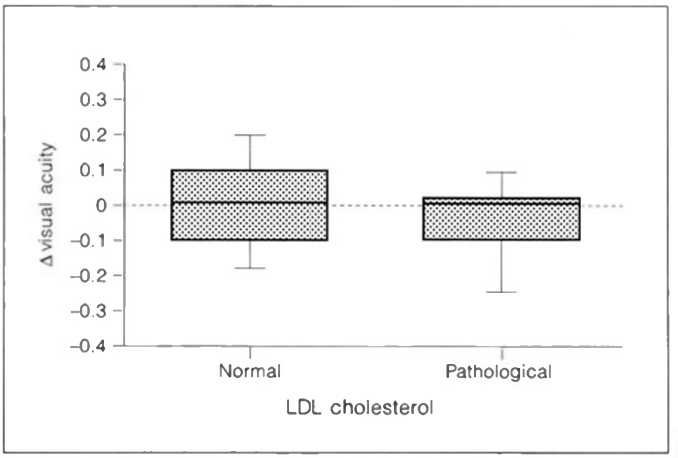

5

Fig. 2–5. Box plots of visual outcome 3–4 months after photocoagulation treatment separately for normal and pathological groups as to triglycerides (**2**), cholesterol (**3**), HDL (**4**) and LDL (**5**). We can see that Δ visual acuity (figured with mean values and standard deviations) is usually higher in the normal than in the pathological group (triglycerides, HDL, LDL).

Discussion

In view of the unpredictable nature of diabetic maculopathy, many factors have to be considered. It has been seen, for example, that in some tests in patients 30 years ago [10–12] where reductions in hard exudates had been effected by lipopenic vegetable diets and lipid-lowering medication, there was unfortunately still no improvement in visual acuity. We must therefore assume that macula edema cannot be eliminated by a decrease in lipid levels alone. In the Wisconsin Epidemiologic Study of Diabetic Retinopathy, a marked tendency to an increasing severity of diabetic retinopathy and to a greater occurence of retinal hard exudate with increasing cholesterol in insulin-using persons was observed [13]. Cholesterol was designated as a significant factor in describing the severity of retinal hard exudate. HDL cholesterol was unrelated to the severity of any diabetic lesions in this study. Hard exudates consist of glyco- and lipoprotein, phospholipid and fatty acids [14]. The usual model in the pathogenesis of hard exudates is an extravasation of intravascular components due to focal leakages from microaneurysms. Hard exudates surround these foci of retinal edema [1] and represent cholesterol-derived lipids that have not been resorbed [13]. All these findings and the fact that hard exudate may be related to significant visual loss, even when other retinal lesions are relatively mild [15,16], seemed to be good reasons to investigate the influence of serum lipids on the results of photocoagulation treatment. In our study, we observed an increased improvement in visual outcome in patients with normal triglyceride and HDL cholesterol values which was statistically significant. A similar trend could be observed for total cholesterol and

LDL cholesterol. Ethical reasons preclude comparing untreated patients of the various lipid groups because the success of laser photocoagulation in patients with macular edema has already been demonstrated [2–4]. A qualifying factor in our study is that we did not distinguish between type 1 and type 2 diabetic patients, but to our knowledge there are no findings that there is any difference in the occurrence of retinal hard exudates between type 1 and type 2 diabetics aged between 40 and 80 years. This study has limitations, and caution must be exercised in the interpretation of its findings. From our finding that serum lipid parameters, especially triglycerides and HDL, influence the course of diabetic macular edema, we are of the opinion that where ophthalmological intervention is anticipated in diabetic patients, and particularly where diabetic macular edema is involved, the serum lipid fractions must be determined. The improvement in visual outcome after photocoagulation treatment can be statistically increased by lipid supervision and appropriate therapy of pathological levels in such patients.

References

1 Bresnick GH: Diabetic macular edema: A review. Ophthalmology 1986;93:989–997.
2 Early Treatment Diabetic Retinopathy Study Reasearch Group: Photocoagulation for diabetic macular edema: ETDRS report number 1. Arch Ophthalmol 1985;103:1796–1806.
3 Early Treatment Diabetic Retinopathy Study Research Group: Treatment techniques and clinical guidelines for photocoagulation of diabetic macular edema: ETDRS report number 2. Ophthalmology 1987;94:761–774.
4 Olk JR: Modified grid argon (blue-green) laser photocoagulation for diffuse diabetic macular edema. Ophthalmology 1986;93:938–950.
5 Kieselbach GF: Laserkoagulation des diabetischen Makulaödems: Erste Ergebnisse des Grid patterns. Spektrum Augenheilkd 1987;1:261–263.
6 Kieselbach G, Juen S: Visusergebnisse bei diabetischer Makulopathie nach zentraler Photokoagulation. Ophthalmologica 1989;199:72–76.
7 Knowler WC, Bennet PH, Ballantine EJ: Increased incidence of retinopathy in diabetics with elevated blood pressure: A six-year follow-up study in Pima Indians. N Engl J Med 1980;302:645–650.
8 Doft BH, Kingsley LA, Orchard TJ, Kuller L, Drash A, Becker D: The association between longterm diabetic control and early retinopathy. Ophthalmology 1984;91:763–769.
9 Howard-Williams J, Hillson RM, Bron A, Audry P, Mann JI, Hockaday TDR: Retinopathy is associated with higher glycemia in maturity-onset type diabetes. Diabetologica 1984;27:198–202.
10 King RC, Dobree JH, Kok DA, Foulds WS, Dangerfield WG: Exudative diabetic retinopathy: Spontaneous changes and effects of a corn oil diet. Br J Ophthalmol 1963;47:666–672.
11 Harrold BP, Marmion VJ, Gough KR: A double-blind controlled trial of clofibrate in the treatment of diabetic retinopathy. Diabetes 1969;18:285–291.
12 Duncan LJP, Cullen JF, Ireland JT, Nolan J, Clarke BF, Oliver MF: A three-year trial of Atromid therapy in exudative diabetic retinopathy. Diabetes 1968;17:458–467.
13 Klein BEK, Moss SE, Klein R, Surawicz TS: The Wisconsin Epidemiologic Study of Diabetic Retinopathy. XIII. Relationship of serum cholesterol to retinopathy and hard exudate. Ophthalmology 1991;98:1261–1265.
14 Sigurdsson R, Beggl S: Organised macular plaques in exudative diabetic maculopathy. Br J Ophthalmol 1980;64:392–397.
15 Aiello LM, Rand LI, Briones JC, Wafai MZ, Sebestyen JG: Diabetic retinopathy. Ophthalmology 1981;88:619–623.
16 Klein R, Klein BEK, Moss SE: Visual impairment in diabetes. Ophthalmology 1984;91:1–9.