The Journal of Arthroplasty 36 (2021) 3507–3512

Contents lists available at ScienceDirect

The Journal of Arthroplasty

journal homepage: www.arthroplastyjournal.org

Primary Hip

# Survivorship of Ceramic-on-Ceramic Total Hip Arthroplasty With Metal-Backed Acetabular Liners at 10 Years

Moritz Wagner, MD [a,*], Hannes Schönthaler [a], Franz Endstrasser, MD [a], Sabrina Neururer PhD [b], Hermann Leitner [b], Alexander Brunner, MD [a]

[a] Department of Orthopaedics and Traumatology, Bezirkskrankenhaus St. Johann in Tirol, St. Johann in Tirol, Tyrol, Austria
[b] Department of Clinical Epidemiology, Tirol Kliniken GmbH, Innsbruck, Tyrol, Austria

ARTICLE INFO

*Article history:*
Received 19 March 2021
Received in revised form
22 May 2021
Accepted 27 May 2021
Available online 2 June 2021

*Keywords:*
THA
BIOLOX
ceramic
metal-backed
mal-seating
liner

ABSTRACT

*Background:* Ceramic-on-ceramic bearings are becoming increasingly popular in primary total hip arthroplasty (THA). To enhance ceramic-on-ceramic liner exchange in case of revision surgery, metal-backed liner systems have been proposed. Little is known about the clinical performance of these implants. The purpose of this study is to evaluate a metal-backed liner implant system for primary THA.
*Methods:* A total of 422 patients (with 468 consecutive THAs) were followed over a mean period of 10 years. All arthroplasties were performed with a cementless stem, a press-fit cup, and a metal-backed liner system. Surgical and clinical data, complications, and revisions were analyzed. The Western Ontario and McMaster Universities Osteoarthritis Index (WOMAC) before surgery and at 1 and 10 years after surgery were compared.
*Results:* The overall 10-year implant survival rate was 93.8%. The survival rate was 97.0% for heads and liners, 97.5% for stem, and 99.3% for acetabular cup. The most common reason for revision was ceramic breakage (2.4%) of the third-generation (BIOLOX forte) acetabular liner. Mean WOMAC score improved significantly from 50.1 before surgery to 13.2 at 1 year after surgery. There was no difference in WOMAC scores between surgical approach and type of bearing at 1 and 10 years after surgery.
*Conclusion:* THA using cementless stem, press-fit cup, and metal-backed liner system provides satisfactory long-term outcomes, with revision rate comparable to that with other systems available in the market. The metal-backed liner system has low risk of mal-seating. Third-generation ceramic liners should be avoided as they seem to be more prone to breakage.



Alumina ceramic-on-ceramic (CoC) bearings have become popular in total hip arthroplasty (THA) [1–3] because of their many advantages. Those include excellent biocompatibility and absence of adverse local tissue reactions, reduced corrosion, negligible wear, and low friction [4–8]. They also have a few disadvantages such as a disturbing squeaking and risk of ceramic breakage [9–12]. In cases of revision surgery with liner exchange, conventional ceramic liners can be detached but not reattached into the acetabular cup, and so a complete acetabular cup exchange may become necessary. Until recently, only a few implant systems have addressed this problem by using special liner designs [13]. In well-seated cups, the revision is usually to ceramic-on-polyethylene (CoP) bearings [14,15]. However, after ceramic fracture, polyethylene liner tends to wear faster, most likely due to the presence of microscopic ceramic debris [16].

The Siocon cup (Falcon Medical, Mödling, Austria), which uses a metal-backed liner system, was developed in 2004 to allow for easy liner exchange during revision surgery and to reduce probability of ceramic breakage.

In our department, the Siocon cup and the Monocon press-fit stem (Falcon Medical) have been used with CoC and CoP bearings for primary THA since 2005. Third-generation liners (BIOLOX forte; CeramTec, Plochingen, Germany) were used until March 2010, and fourth-generation liners (BIOLOX delta) after that. To our

Funding: This research did not receive any specific grant from funding agencies in the public, commercial, or not-for-profit sectors. The authors received no financial support for the research, authorship, and/or publication of this article.

No author associated with this paper has disclosed any potential or pertinent conflicts which may be perceived to have impending conflict with this work. For full disclosure statements refer to https://doi.org/10.1016/j.arth.2021.05.038.

* Address correspondence to: Moritz Wagner, MD, Department of Orthopaedics and Traumatology, Bezirkskrankenhaus St. Johann in Tirol, Bahnhofstrasse 14, 6380 St. Johann in Tirol, Tyrol, Austria.

https://doi.org/10.1016/j.arth.2021.05.038
0883-5403/

knowledge, the efficacy and safety of these implants have never been clinically evaluated. Other implants with metal-backed liners are also available but there is little information in the literature regarding clinical outcomes, complications, and revision rates with the use of metal-backed liners.

The purpose of this single-center study is to evaluate the long-term clinical outcomes after primary THA with the Siocon cup and the Monocon stem. We hypothesized that the Siocon cup and the Monocon stem would be safe and effective for THA and that the fracture rates would be lower with metal-backed ceramic liners than with conventional ceramic liners.

## Patients and Methods

This study was approved by the Independent Ethics Committee of the Medical University Innsbruck, Austria (Process No: 1224/2020) and all procedures were in accordance with the Declaration of Helsinki. Written consent was obtained from all patients. None of the authors were involved in primary patient care.

The Siocon cup (Falcon Medical) is a cementless spherical press-fit cup made of forged TiAl6V4 alloy and coated with pure titanium with roughness of 220-250 μm. It is available in diameters ranging from 44 to 70 mm, in 2-mm increments. According to the outer diameter, there are 4 liner types (type A: 38.5 mm, type B: 42 mm, type BB: 44 mm, and type C: 46.5 mm) that are all compatible with 28-mm, 32-mm, and 36-mm heads. The liners used in this study contained third- or fourth-generation ceramics, preassembled with a titanium metal shell, that is, were metal-backed (Fig. 1). The cups have been implanted after thorough preparation of the acetabulum, the surgeons aimed inclination angle was 35°-50° and aimed anteversion was 5°-25°.

The Monocon stem (Falcon Medical) is a nonmodular tapered stem with a lateral tapered tip. There are 4 variants, with different neck lengths and caput-collum-diaphysis angles. A total of 12 stem sizes are available; the smallest (size 1) has length of 131 mm, and the largest (size 12) has length of 178 mm. The 12/14 mm cone is designed for use with ceramic heads (CeramTec) or with metal heads with the same cone specification (Fig. 2).

The inclusion criteria for this study were primary THA with the Monocon stem and the Siocon cup with a CoC bearing. Between 2008 and 2012, a total of 538 consecutive THAs (504 patients) were identified. Of those, 82 patients died within 10 years after surgery. The remaining 422 patients were included for prospective follow-up. The number of THAs, site, patient gender, indication for surgery, and surgical approach are summed up in Table 1. All acetabular liners had the metal-backed design (Fig. 3). Patients were followed up for a mean period of 10.02 years (standard deviation [SD], 2.18). Demographic characteristics, indication for surgery, body mass index (BMI), type of surgical approach, surgery time, types and sizes of implants, length of hospital stay, perioperative and postoperative complications, and revision surgeries, if any, were documented in our institution's medical database. Patients were asked to fill up a Western Ontario and McMaster Universities Osteoarthritis Index (WOMAC) questionnaire before surgery, at 1 year after surgery, and at the final follow-up. The WOMAC score can range from 0 (best) to 100 (worst). A difference of more than 10 points between 2 scores is considered clinically relevant [17,18].

Our data were matched with the Tyrolean Joint Replacement Registry (Austria) data to detect revision surgeries that were performed in other hospitals. In addition, we interviewed all patients by phone at the time of the final follow-up and asked for information on revisions or complications that had occurred since the initial surgery. Surgical reports of all revision arthroplasties were obtained. The exchanged components were documented. Reasons for revision were grouped into categories. The end points of this



**Fig. 1.** The Siocon press-fit hemispherical cup with a fourth-generation ceramic liner.

**Fig. 2.** The Monocon press-fit stem with a fourth-generation ceramic head.

**Table 1**
Patient's Demographics, Bearing, Diagnosis, and Surgical Approach of This Study Cohort.

| Demographics | n | % |
|---|---|---|
| Gender | | |
| Male | 207 | 44.2 |
| Female | 261 | 55.8 |
| Total | 468 | 100 |
| Site | | |
| Left | 233 | 49.8 |
| Right | 235 | 50.2 |
| Total | 468 | 100 |
| Bilateral | | |
| Bilateral | 92 | 19.6 |
| Unilateral | 376 | 80.4 |
| Total | 468 | 100 |
| Bearing | | |
| BIOLOX forte | 258 | 55.1 |
| BIOLOX delta | 210 | 44.9 |
| Total | 468 | 100 |
| Diagnosis | | |
| Osteoarthritis | 413 | 88.2 |
| Developmental dysplasia | 16 | 3.4 |
| Post-traumatic osteoarthritis | 10 | 2.1 |
| Aseptic femoral head necrosis | 19 | 4.1 |
| Legg-Calvé-Perthes disease | 8 | 1.7 |
| Others | 2 | 0.4 |
| Total | 468 | 100 |
| Surgical approach | | |
| Anterior | 12 | 2.6 |
| Anterolateral | 637 | 78.2 |
| Transgluteal | 89 | 19 |
| Total | 468 | 100 |

study were either death or revision arthroplasty with any type of hardware exchange. The primary outcome parameters were implanted survival and WOMAC scores.

### *Statistical Analysis*

Implant survival in years was calculated, and Kaplan-Meier survival analysis was performed for each implant component.



**Fig. 3.** A fourth-generation metal-backed liner.

**Table 2**
WOMAC Scores Before Surgery, at 1 y After Surgery, and at 10 y After Surgery (0 = Best, 100 = Worst).

| | Group | Mean | SD |
|---|---|---|---|
| WOMAC preoperative, n = 396 of 422, Completeness: 94% | Pain | 46.7 | 21.2 |
| | Stiffness | 51.5 | 25.6 |
| | Function | 52.1 | 21.1 |
| | Total | 50.1 | 20.1 |
| WOMAC 1 y after surgery, n = 402 of 422, Completeness: 95%, $P < .001$[a] | Pain | 9.7 | 15.19 |
| | Stiffness | 16.7 | 19.5 |
| | Function | 13.2 | 16.9 |
| | Total | 13.2 | 16.2 |
| WOMAC 10 y after surgery, n = 270 of 422, Completeness: 64%, $P = .236$[b] | Pain ($P = .002$[b]) | 7.8 | 14.0 |
| | Stiffness | 16.1 | 18.0 |
| | Function | 13.2 | 18.2 |
| | Total | 12.3 | 15.2 |

SD, standard deviation; WOMAC, Western Ontario and McMaster Universities Osteoarthritis Index.
[a] WOMAC before surgery vs 1 y after surgery.
[b] WOMAC 1 y before surgery vs 10 y after surgery.

Patient-specific and operation-specific parameters were checked for normal distribution, and their correlation with the outcome parameters was assessed using Pearson correlation. The means of continuous variables were compared between groups using one-way analysis of variance with Tukey post hoc testing. Categorical data were compared using the chi-squared test. Statistical significance was at $P \leq .05$ for all tests.

## Results

The mean age of the patients at the time of arthroplasty was 63.4 years (range, 27-80; SD, 10.5).

The mean BMI before surgery was 27.3 kg/m$^2$ (range, 18.0-40.5; SD, 3.8); patients with higher BMI had lower WOMAC function score at 1 year after surgery ($r = 0.228$; $P < .001$).

The mean length of procedure was 65.1 minutes (range, 27-206; SD, 18.8). In 12 of 468 (2.5%) hips with severe osseous defect of the acetabular roof required autograft osteoplasty. Patients with increased length of procedure also required longer periods of hospital stay ($r = 0.371$; $P < .001$) and had decreased implant survival in years ($r = -0.262$; $P < .001$). Length of procedure had no influence on WOMAC scores. Mean length of hospital stay was 10.4 days (range, 4-37; SD, 2.9). Longer periods of hospital stay were associated with worse WOMAC scores at 1 year after surgery ($r = 0.227$; $P < .001$), but not to at 10 years after surgery ($r = 0.089$; $P = .139$).

Absolute numbers and the return rate of the WOMAC scores are summed up in Table 2. The surgical approach, type of liner, and indication for surgery (diagnosis) had no influence on WOMAC scores. Neither did early complications, such as blood loss requiring transfusion (4.2%), wound healing disorders (1.5%), thromboembolism (0.5%), and dislocations not requiring surgical revision (0.3%) influence the WOMAC scores at 1 year after surgery. One patient reported on audible squeaking, which was only little disturbing. This patient had adequate cup positioning and good overall WOMAC scores.

In a subgroup of 28 patients, there was worsening of the hip status at final follow-up, as indicated by change in overall WOMAC scores by more than 10 points; this degree of change is considered clinically significant. These patients were contacted by telephone to determine whether there was any actual subjective deterioration in their hip status or if the changes in their WOMAC scores were due to comorbidities unrelated to the hip. Among the 28 patients, 23 admitted that comorbidities such as lower back pain, knee pain, and neurological diseases had affected their WOMAC scores. The

**Table 3**
Reasons Leading to Revision in 468 Primary THAs Grouped by Liner Type, Including Survival, Age, and BMI.

| | Total Revisions | BIOLOX forte | BIOLOX delta | Survival (y) | Age (y) | BMI (kg/m$^2$) |
|---|---|---|---|---|---|---|
| Ceramic liner breakage (only liner type 36C affected) | | | | | | |
| N | **11 (2.3%)** | **11 (2.3%)** | **0 (0%)** | **11** | **11** | **11** |
| Mean | | | | 6.1 | 59.7 | 26.7 |
| SD | | | | 2.8 | 9.717 | 4.9 |
| Periprosthetic joint infection | | | | | | |
| N | **6 (1.3%)** | **5 (1.1%)** | **1 (0.2%)** | **6** | **6** | **6** |
| Mean | | | | 6.1 | 54.8 | 28.9 |
| SD | | | | 3.2 | 9.0 | 4.9 |
| Periprosthetic fracture | | | | | | |
| N | **5 (1.1%)** | **2 (0.4%)** | **3 (0.6%)** | **5** | **5** | **5** |
| Mean | | | | 6.7 | 69.6 | 23.0 |
| SD | | | | 3.7 | 15.2 | 4.4 |
| Aseptic stem loosening | | | | | | |
| N | **4 (0.8%)** | **2 (0.4%)** | **2 (0.4%)** | **4** | **4** | **4** |
| Mean | | | | 5.6 | 61.7 | 27.9 |
| SD | | | | 4.79108 | 8.342 | 4.8 |
| Joint dislocation | | | | | | |
| N | **2 (0.4%)** | **1 (0.2%)** | **1 (0.2%)** | **2** | **2** | **2** |
| Mean | | | | 4.7 | 68.0 | 33.7 |
| SD | | | | 4.2 | 14.1 | 0.01 |
| Incomplete liner seating | | | | | | |
| N | **1 (0.2%)** | **0 (0%)** | **1 (0.2%)** | **1** | **1** | 1 |
| Mean | | | | 0.01 | 86.0 | 29.4 |
| SD | | | | – | – | – |
| Total revisions | | | | | | |
| N | **29 (6.2%)** | **21 (4.5%)** | **8 (1.7%)** | **29** | **29** | **24** |
| Mean | | | | 5.8 | 62.2 | 27.2 |
| SD | | | | 3.3 | 12.0 | 5.1 |
| Statistical significance | | | | | | |
| *P* | | **.018** | | .625 | .086 | .138 |

BMI, body mass index; SD, standard deviation; THA, total hip arthroplasty.

remaining 5 patients were readmitted to our department for a radiological work-up, but none of them had any signs of osteolysis, implant loosening, or other implant-related pathology.

The overall implant survival rate was 93.8%. The survival rates were 97.0% for head and liner, 97.5% for stem, and 99.3% for cup. Reasons leading to revision can be found in Table 3. The single most common reason for revision was ceramic liner breakage, only occurring with third-generation (BIOLOX forte) liners type "36C" ($P = .018$; Fig. 4). In all patients with ceramic breakage, the acetabular cup inclination (mean, 41.1°; range, 35°-49°; SD, 4.1°) and anteversion (12.4°, 8°-17°, 2.4°) was measured according to the method of Widmer [19]. There were no cases of breakage of ceramic heads and no cases of breakage of fourth-generation ceramic liners (BIOLOX delta).

## Discussion

The results of this study confirm our hypothesis that the Siocon cup and the Monocon stem are both safe and effective implants for THA. However, the results do not support our hypothesis that the metal-backed liner design can reduce the rate of breakage of ceramic liners.

The overall survival rate of the Siocon cup and the Monocon stem is comparable to the survival rates of other implants [20–22]. Previous studies have found higher rates of breakage with BIOLOX forte CoC bearings than with other CoC implant systems [10,23,24]. In our study, there was no case of breakage of liners with BIOLOX delta; this was most likely due to the high material strength of BIOLOX delta [9,10,25].

The performance of metal-backed liners of other manufacturers have been reported in the past. Carvajal et al [26] reported incomplete seating in the acetabular shell as a possible mode of failure of metal-backed liners. In our study, we observed this complication in only 1 patient. Incomplete seating of the metal-backed liner in the acetabular shell may be due to the structural design of the implant [27]; the Siocon cup has a profound cone, which seems to facilitate seating.

THA is one of the most effective procedures to decrease pain and improve quality of life [4]. Our patients had significant improvement in the WOMAC score at 1 year after surgery. In our cohort, the decision to operate was made at a mean WOMAC score of 51.49 (SD, 20.6), which is little higher than the score of 45.8 (SD, 18.5) reported by Joly et al [28] after analysis of the Alberta Bone and Joint Health Institute (ABJHI) Data Repository.

The majority of patients reported good results at 10 years after surgery. Only a small subgroup of patients showed deterioration in the final WOMAC score, but none of these could be attributed to hip pathologies. We therefore conclude that the tested implant is safe and effective with ability to provide a satisfactory long-term outcome [29].

Breakage is a common complication with third-generation ceramics. CeramTec claims a 54%-80% increase in maximum load to failure with the novel fourth-generation ceramic heads under in vitro conditions. Until recently, in vivo evaluations were rare. Data from national joint registries [10] and clinical studies [24,30,31] now confirm the superior biomechanical properties of fourth-generation ceramics compared to earlier generations.

In our cohort, only third-generation ceramic liners with large inner diameters (type: 36C) broke, with the macroscopic mode of failure being breakage at the deepest concavity of the liner (Fig. 5). Radiographic analysis showed adequate implant positioning in those cases. Broken liners were assessed in a specialized laboratory for tribological analysis, and edge wear due to edge loading could be excluded in all our cases of ceramic breakage. Edge wear due to edge loading has been previously defined as one of the mechanisms leading to accelerated wear of liners and stripe wear of ceramic heads [5]. The absence of wear and the presence of isolated liner base breakage of third-generation type 36C liners suggest a

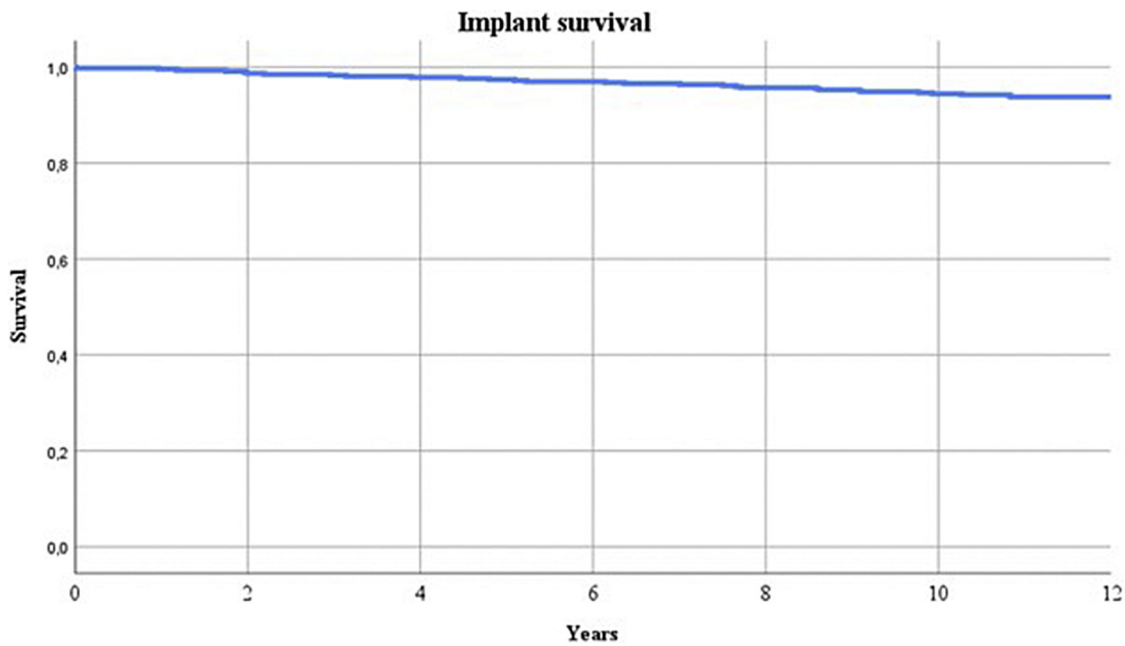


**Fig. 4.** Kaplan-Meier statistics of implant survival in years.

structural weakness. Further biomechanical research is necessary to understand the reasons and guide future implant designs. Fortunately, there was not a single case of ceramic breakage in fourth-generation ceramics.

The strengths of this study are the prospective follow-up at 10 years, the consideration of clinical parameters, the usage of a joint replacement registry to identify revision surgeries, and the use of patient-reported outcome measurement (WOMAC). Only few patients were lost to follow-up, and valid assessment of all complications and revisions was performed. The study limitations include the relatively small sample size of 468 THAs (especially when compared to the numbers in national joint registries) and the fact that this was a single-center evaluation; implant performance may be different in other orthopedic centers.

## Conclusion

The Siocon cup and the Monocon stem appear to be safe and effective implants for primary THA, capable of providing satisfactory long-term outcomes. However, it may be best to avoid their use in conjunction with third-generation CoC bearings, and especially in conjunction with 36-mm heads (type: 36C). Although use of metal-backed liners may have advantages during revision surgery, the impact of the metal back on the biomechanical properties of ceramic needs further assessment.

**Fig. 5.** Typical base-breakage of a third-generation metal-backed ceramic liner.

## Acknowledgments

The authors wish to thank all individuals who foresaw the importance and implemented the Tyrolean Joint Replacement Registry many years ago: M. Blauth; M. Czornik; I. Delmarko; B. Huter; M. Krismer; H. Rinner; and R. Siorpaes.

## References

[1] Tsikandylakis G, Overgaard S, Zagra L, Kärrholm J. Global diversity in bearings in primary THA. EFORT Open Rev 2020;5.
[2] Heckmann ND, Sivasundaram L, Stefl MD, Kang HP, Basler ET, Lieberman JR. Total hip arthroplasty bearing surface trends in the United States from 2007 to 2014: the rise of ceramic on polyethylene. J Arthroplasty 2018;33.
[3] Rajaee SS, Trofa D, Matzkin E, Smith E. National trends in primary total hip arthroplasty in extremely young patients. A focus on bearing surface usage. J Arthroplasty 2012;27.
[4] Learmonth ID, Young C, Rorabeck C. The operation of the century: total hip replacement. Lancet 2007;370.
[5] Al-Hajjar M, Fisher J, LTipper J, Williams S, Jennings LM. Wear of 36-mm BIOLOX delta ceramic-on-ceramic bearing in total hip replacements under edge loading conditions. Proc Inst Mech Eng H 2013.
[6] Zagra L, Gallazzi E. Bearing surfaces in primary total hip arthroplasty. EFORT Open Rev 2018;3:217–24.
[7] Lee YK, Yoon BH, Choi YS, Jo WL, Ha YC, Koo KH. Metal on metal or ceramic on ceramic for cementless total hip arthroplasty: a meta-analysis. J Arthroplasty 2016;31.
[8] Hjorth MH, Mechlenburg I, Soballe K, Roemer L, Jakobsen SS, Stilling M. Higher prevalence of mixed or solid pseudotumors in metal-on-polyethylene total hip arthroplasty compared with metal-on-metal total hip arthroplasty and resurfacing hip arthroplasty. J Arthroplasty 2018;33.
[9] Lee YK, Ha YC, Yoo JI, Jo WL, Kim KC, Koo KH. Mid-term results of the BIOLOX delta ceramic-on-ceramic total hip arthroplasty. Bone Joint J 2017;99B:741–8.
[10] Howard DP, Wall PDH, Fernandez MA, Parsons H, Howard PW. Ceramic-on-ceramic bearing fractures in total hip arthroplasty. Bone Joint J 2017;99B:1012–9.
[11] Salo PP, Honkanen PB, Ivanova I, Reito A, Pajamäki J, Eskelinen A. High prevalence of noise following Delta ceramic-on-ceramic total hip arthroplasty. Bone Joint J 2017;99-B.

[12] Inagaki K, Iida S, Miyamoto S, Suzuki C, Nakatani T, Shinada Y, et al. Natural history of noise and squeaking in cementless ceramic-on-ceramic total hip arthroplasty. J Orthop 2020;21.
[13] Miller AN, Su EP, Bostrom MPG, Nestor BJ, Padgett DE. Incidence of ceramic liner malseating in Trident® acetabular shell. Clin Orthop Relat Res 2009;467.
[14] Matar WY, Restrepo C, Parvizi J, Kurtz SM, Hozack WJ. Revision hip arthroplasty for ceramic-on-ceramic squeaking hips does not compromise the results. J Arthroplasty 2010;25(SUPPL. 6).
[15] Olmedo-Garcia NI, Zagra L. High risk of complications using metal heads after ceramic fracture in total hip arthroplasty. Hip Int 2019;29.
[16] Zagra L, Bianchi L, Giacometti Ceroni R. Revision of ceramic fracture with ceramic-on-polyethylene in total hip arthroplasty: medium-term results. Injury 2016;47.
[17] Rolfson O, Eresian Chenok K, Bohm E, Lübbeke A, Denissen G, Dunn J, et al. Patient-reported outcome measures in arthroplasty registries: report of the patient-reported outcome measures working group of the International Society of Arthroplasty Registries: Part I. Overview and rationale for patient-reported outcome measures. Acta Orthop 2016;87:3–8.
[18] Clement ND, Bardgett M, Weir D, Holland J, Gerrand C, Deehan DJ. What is the minimum clinically important difference for the WOMAC index after TKA? Clin Orthop Relat Res 2018;476:2005–14.
[19] Widmer KH. A simplified method to determine acetabular cup anteversion from plain radiographs. J Arthroplasty 2004;19.
[20] Taylor JW, Frampton C, Rothwell AG. Long-term survival of total hip arthroplasty using implants from different manufacturers. J Arthroplasty 2018;33.
[21] Chaudhry H, MacDonald SJ, Howard JL, McCalden RW, Naudie DD, Vasarhelyi EM. Clinical outcomes and midterm survivorship of an uncemented primary total hip arthroplasty system. J Arthroplasty 2020;35.
[22] Hemmilä M, Karvonen M, Laaksonen I, Matilainen M, Eskelinen A, Haapakoski J, et al. Survival of 11,390 Continuum cups in primary total hip arthroplasty based on data from the Finnish Arthroplasty Register. Acta Orthop 2019;90.
[23] Kim SC, Lim YW, Jo WL, Park HW, Bin Han S, Kwon SY, et al. Fourth-generation ceramic-on-ceramic THA results in improvements in midterm outcomes compared to third-generation THA but does not resolve noise problems: a cohort study of a single-hip system. BMC Musculoskelet Disord 2019;20.
[24] Kang BJ, Ha YC, Hwang SC, Lee YK, Koo KH. Midterm results of large diameter Biolox forte ceramic head on delta ceramic liner articulation in total hip arthroplasty. J Arthroplasty 2014;29.
[25] Castagnini F, Bordini B, Tassinari E, Stea S, Ancarani C, Traina F. Delta-on-delta ceramic bearing surfaces in revision hip arthroplasty. J Arthroplasty 2019;34.
[26] Carvajal Alba JA, Schiffman ED, Scully SP, Parvataneni HK. Incomplete seating of a metal-backed alumina liner in ceramic-on-ceramic total hip arthroplasty. Orthopedics 2010;33.
[27] Langdown AJ, Pickard RJ, Hobbs CM, Clarke HJ, Dalton DJN, Grover ML. Incomplete seating of the liner with the Trident acetabular system: a cause for concern? J Bone Joint Surg Br 2007;89.
[28] Joly DA, Ludwig T, Mahdavi S, Khong H, Piroozfar SG, Sharma R. Does age influence patient-reported outcomes in unilateral primary total hip and knee arthroplasty? J Arthroplasty 2020;35.
[29] Ghomrawi HMK, Mancuso CA, Dunning A, Gonzalez Della Valle A, Alexiades M, Cornell C, et al. Do surgeon expectations predict clinically important improvements in WOMAC scores after THA and TKA? Clin Orthop Relat Res 2017;475.
[30] Beckmann NA, Gotterbarm T, Innmann MM, Merle C, Bruckner T, Kretzer JP, et al. Long-term durability of alumina ceramic heads in THA. BMC Musculoskelet Disord 2015;16.
[31] Lee YK, Ha YC, Yoo J-I, Jo WL, Kim K-C, Koo KH, et al. Mid-term results of the BIOLOX delta ceramic-on-ceramic total hip arthroplasty contemporary ceramic-on-ceramic articulations have the lowest rate of wear. Bone Joint J 2017:99–741.